

# **Rife**

# **Frequencies Used for**

# **Healing**

# Science of Frequencies in Healing


Rife built his research off of studies conducted by a 20th-century scientist, Dr. Albert Abrams, who believed:

All matter vibrates (that vibration is what we call frequency), and vibrations were specific to the type of matter and what it's made of.

Building on Dr. Abrams' research, Dr. Rife theorized that cancer cells and pathogens could be targeted by outside electromagnetic frequencies (EMFs). Then, the cells would undergo apoptosis (cell death, where it will either implode or explode). This was the genesis of the Rife machine, a tool that matches the specific frequency of different cancer cells and pathogens delivering low-energy electromagnetic waves to the body.


# Science of Frequencies in Healing

In the 1920s and '30s, Dr. Royal Raymond Rife—a bacteriologist studying at John Hopkins University—observed that viruses, bacteria, and cancer cells had their own resonance frequencies.



Rife Universal Light microscope was used to determine the mortal oscillatory frequency that destroyed pathogens. By subjecting the pathogen with the same frequency that it vibrated, Rife was able to explode it without harming any surrounding cells.

# Rife Technology



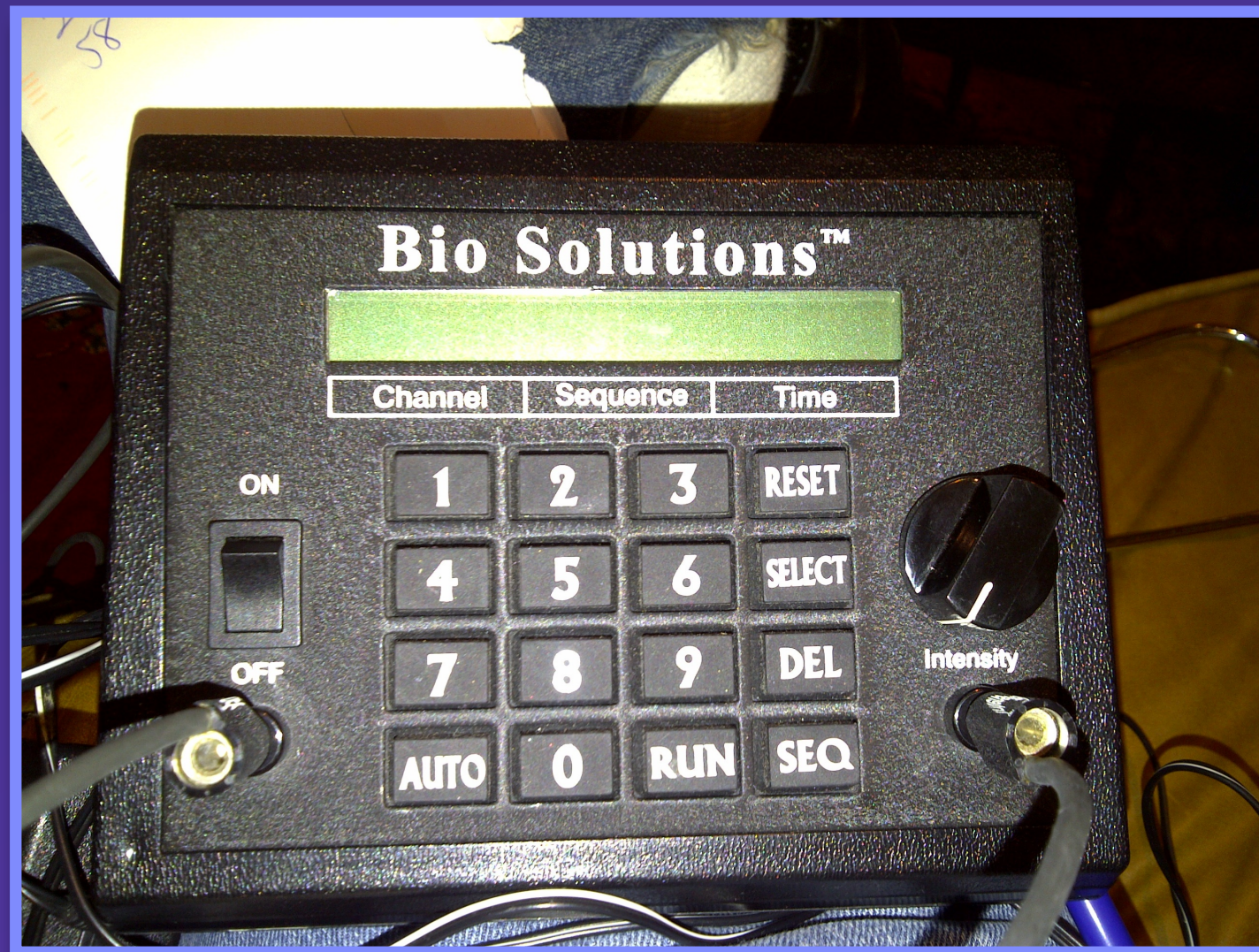Royal  
Raymond Rife  
1888-1972



With the frequency instrument treatment, no tissue is destroyed and no pain is felt. The virus or bacteria is destroyed and the body then recovers itself naturally from the toxic effect of the virus or bacteria.

# Science of Frequencies in Healing

In 1934, Dr. Rife conducted experiments under the auspices of the University of Southern California and direction of Dr. Milbank Johnson, Dr. Arthur Kendall, and E.C. Rosenow; 16 terminally ill cancer patients were treated. According to some claims, his rife machine for cancer cured 14 of the patients, and the other two stayed for more intensive treatments. Four weeks later, the other two were reported to be cured.

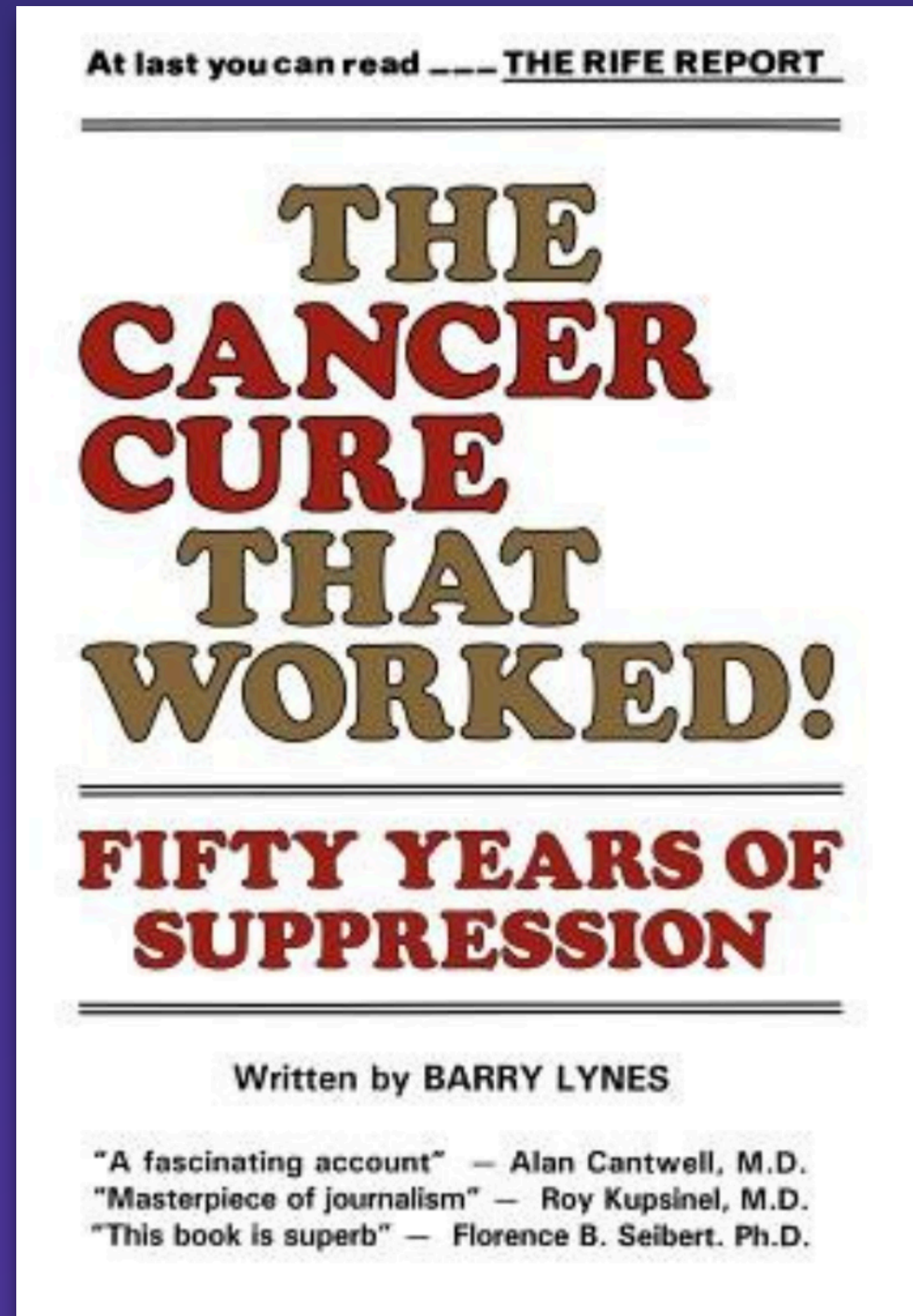


*The Cancer Cure that Worked: Fifty Years of Suppression*

Barry Lynes

Earlier version of a Rife Generator

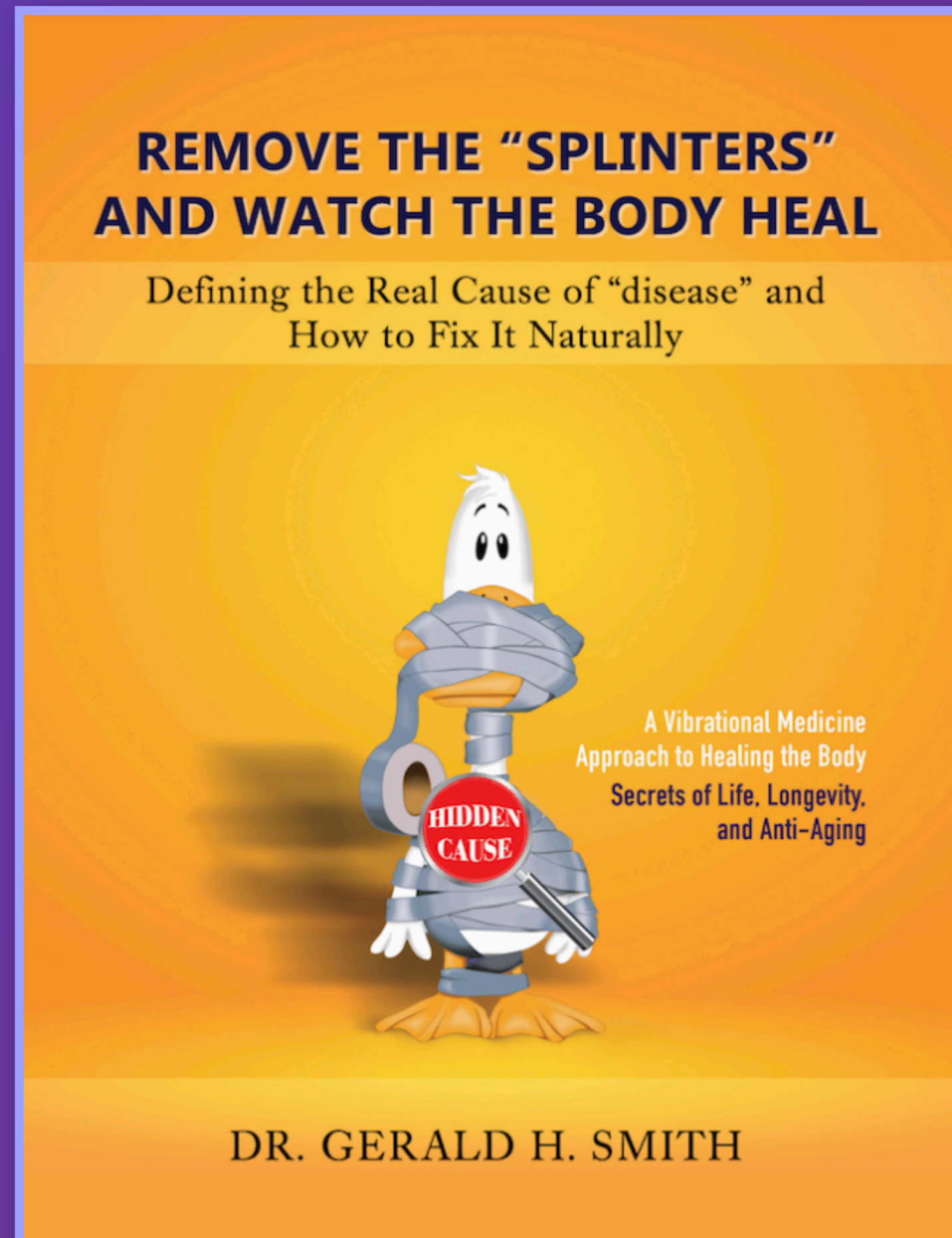
# A Must Read Book



An in depth history on Rife's background and research and the development of the frequency generator.

Available on Amazon  
Barry Lynes

# NEW BOOK RELEASE



In an era of medical deceit, telling  
the truth is a revolutionary act!

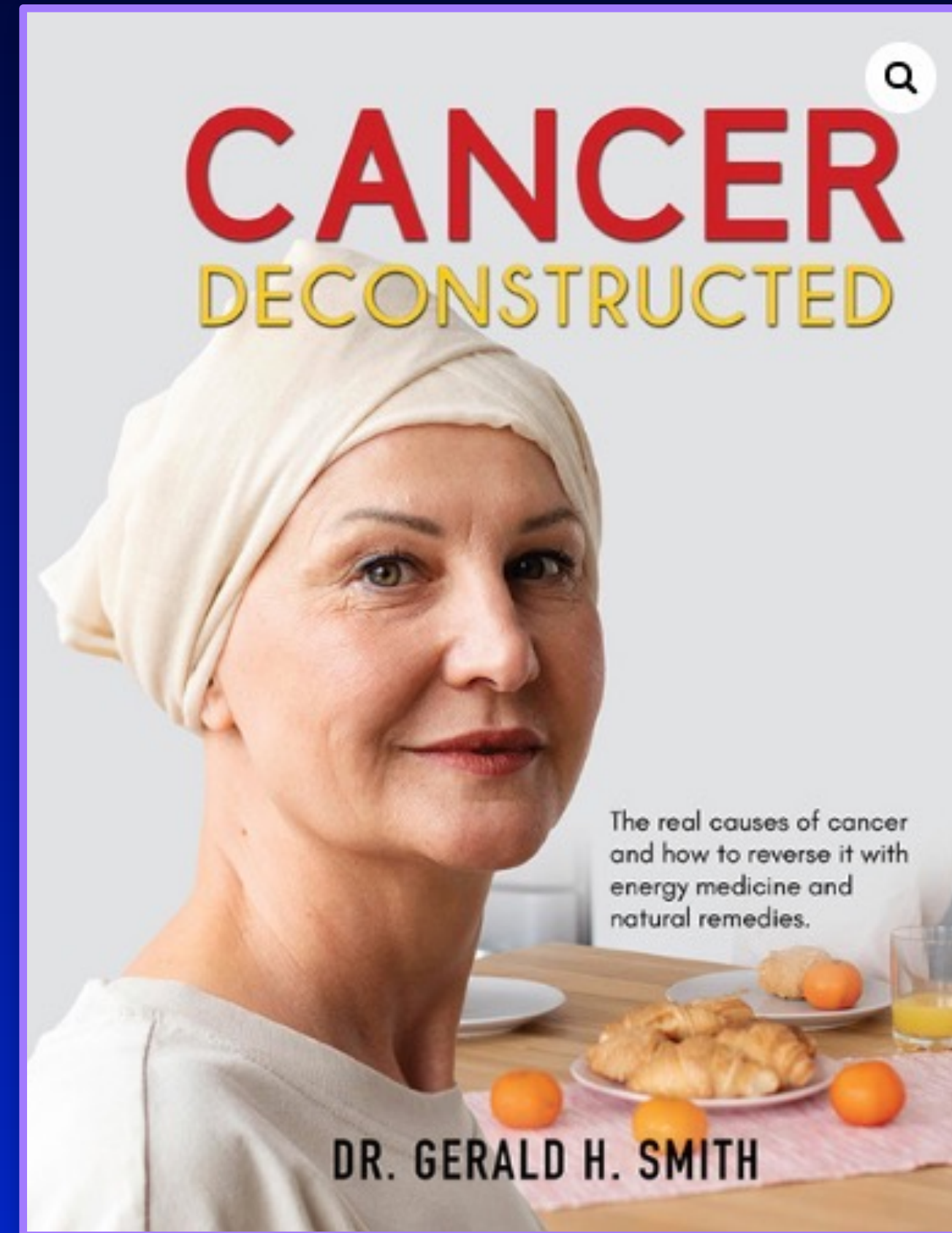
**Remove the "Splinters" and  
Watch:**

Facial pain, TMJ, cancer, auto-  
immune diseases, Alzheimer's,  
chronic pain, migraines, bipolar  
disorder, CHF, seizures, vertigo  
and many more "diseases"  
**DISAPPEAR !**

**e-book: available at [www.ghsdoc.com](http://www.ghsdoc.com) and [amazon.com](http://amazon.com)**

# Cancer Deconstructed

Available on Amazon



Cancer Deconstructed presents the paradigm of defining the “splinters” or initiating factors that triggered the cancer. By removing the causes, the cancer cells go back to normal.



# Shingles in a Tooth

# Idiopathic Tooth Pain



Csilla had tooth pain in her lower right first bicuspid for four years. All conventional diagnostic testing including x-rays revealed no pathology. Using energetic testing, herpes zoster (Shingles) was diagnosed. The patient was treated with the Rife frequencies and three days later her four years of tooth pain totally disappeared and never returned.

# Oral Shingles

# Chronic Post-Extraction Pain



Melissa P. suffered searing pain in the maxillary left third molar extraction site for one year following removal of her third molar. No one made the diagnosis of shingles! Two months prior to the extraction Melissa had an out break of shingles on her back. No one connected the dots.

# Uncommon Dental Issues

## Ten Years of Severe Oral Pain



*Oral Herpes Zoster*

# **Dental Vertigo Connection**

# Vertigo Dental Connection




Duncan Alderson

Johns Hopkins and Hershey Medical as well as numerous neurologists could not resolve Duncan's 15 years of suffering vertigo.

**Dx:** CMV was present in his lower left second molar root canal tooth that migrated to his left inner ear.

**Tx:** Two months of treatment with Biofrequencies destroyed the CMV and totally resolved his vertigo.

# DENTAL WHOLE BODY CONNECTION

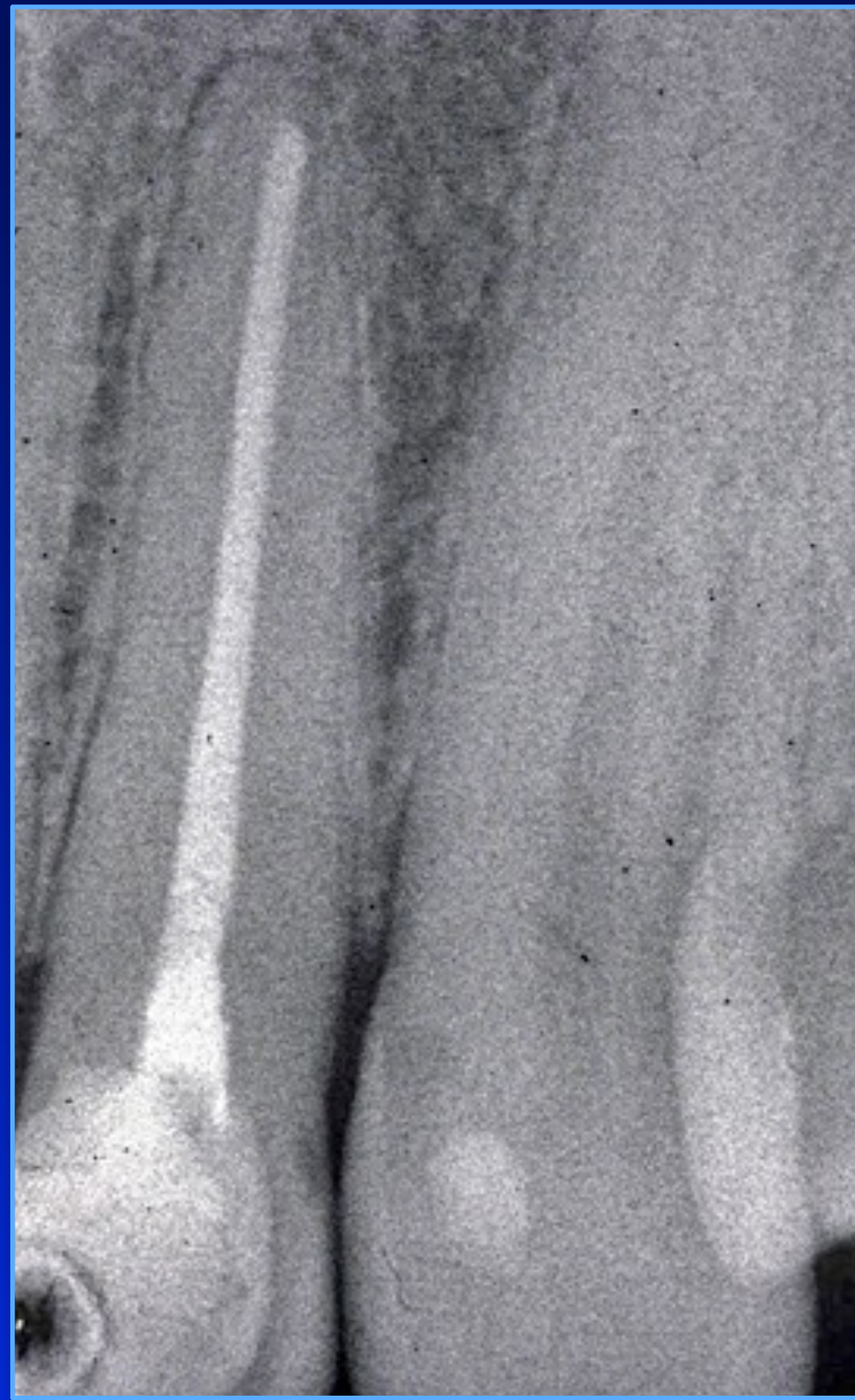


**15 YEARS POSITIONAL VERTIGO**



# Dental Rheumatoid Arthritis Connection

1973



Root Canal at age 29

Age 30 - First signs of rheumatoid arthritis: swollen knees appeared one year after root canal therapy performed in tooth #10.

1974-2004 -Patient placed on prednisone, methotrexate and Enbrel (yearly cost \$13,500) Enbrel is primarily used to block the tumor necrosis factor alpha (TNF alpha), which the body produces during the inflammatory response.

2004 - Direct Resonance testing: Dx Streptococcus viridans in root canal tooth. Three treatments with the Rife frequencies eliminated use of Enbrel and reduced swelling and pain by 98 percent.

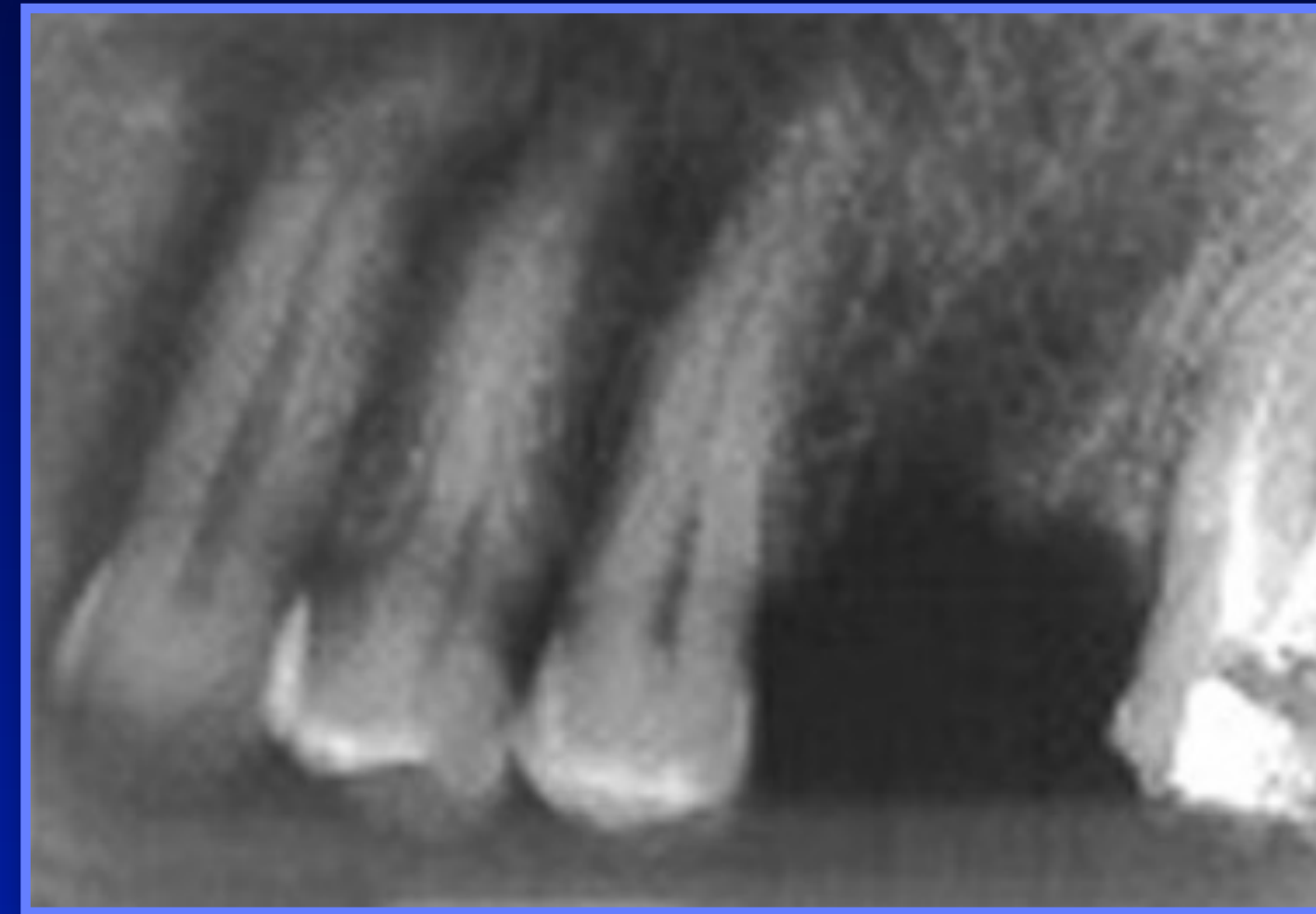
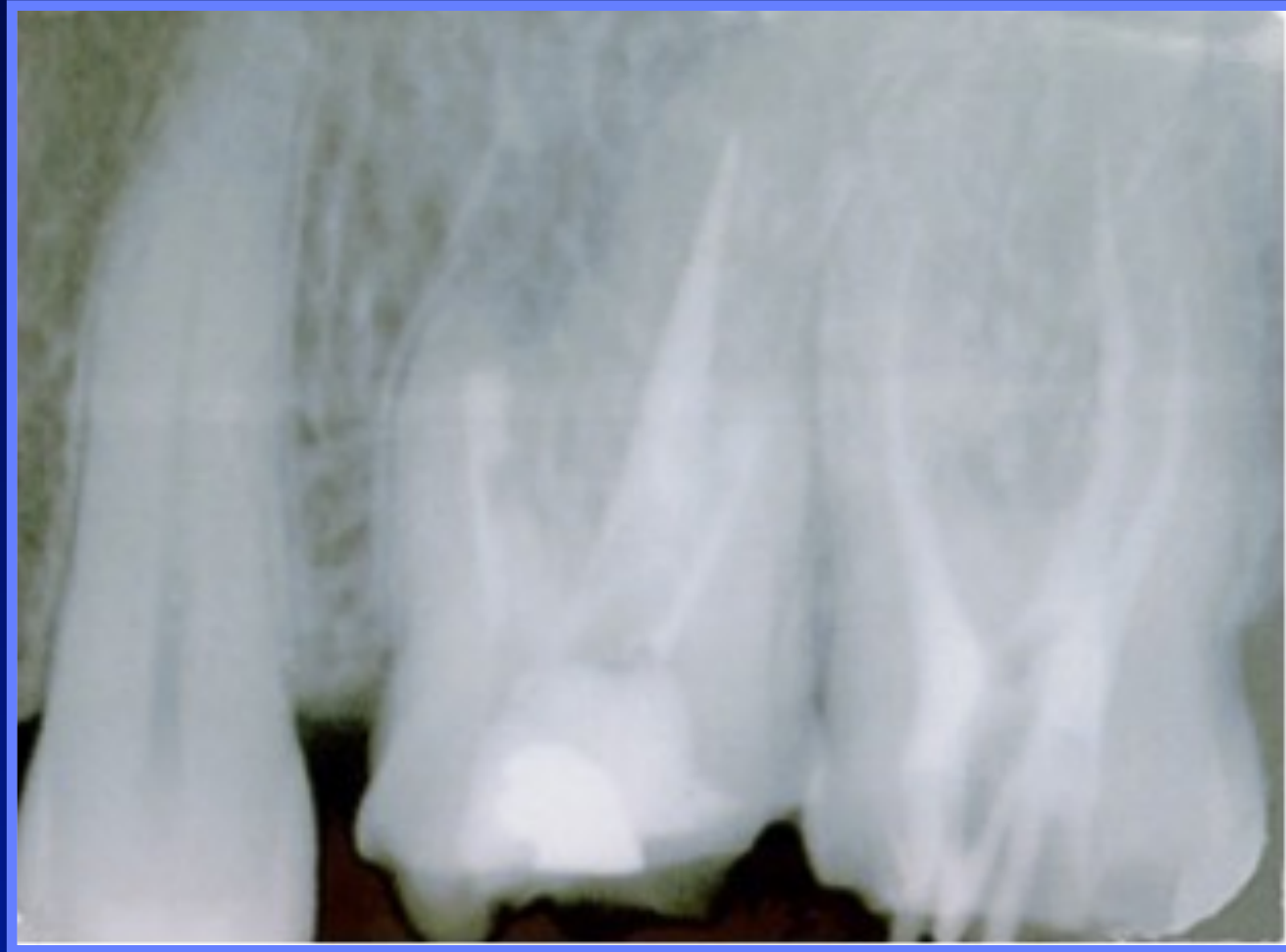
# **Dental Atypical Facial Pain Connection**

# DENTAL HISTORY

- First root canal (upper left first molar): Treatment unsuccessful; much pain following treatment.
- Apicoectomy May 1999: apicoectomy performed by an endodontist. Treatment was unsuccessful. Constant pain still present.
- Extraction September 1999: Oral surgeon removed failed root canalled tooth.
- Second root canal (upper left second molar performed. Pain level not affected.

Orthodontist and oral surgeon were consulted regarding possible TMJ problem. Both concluded that no definitive problem could be seen.

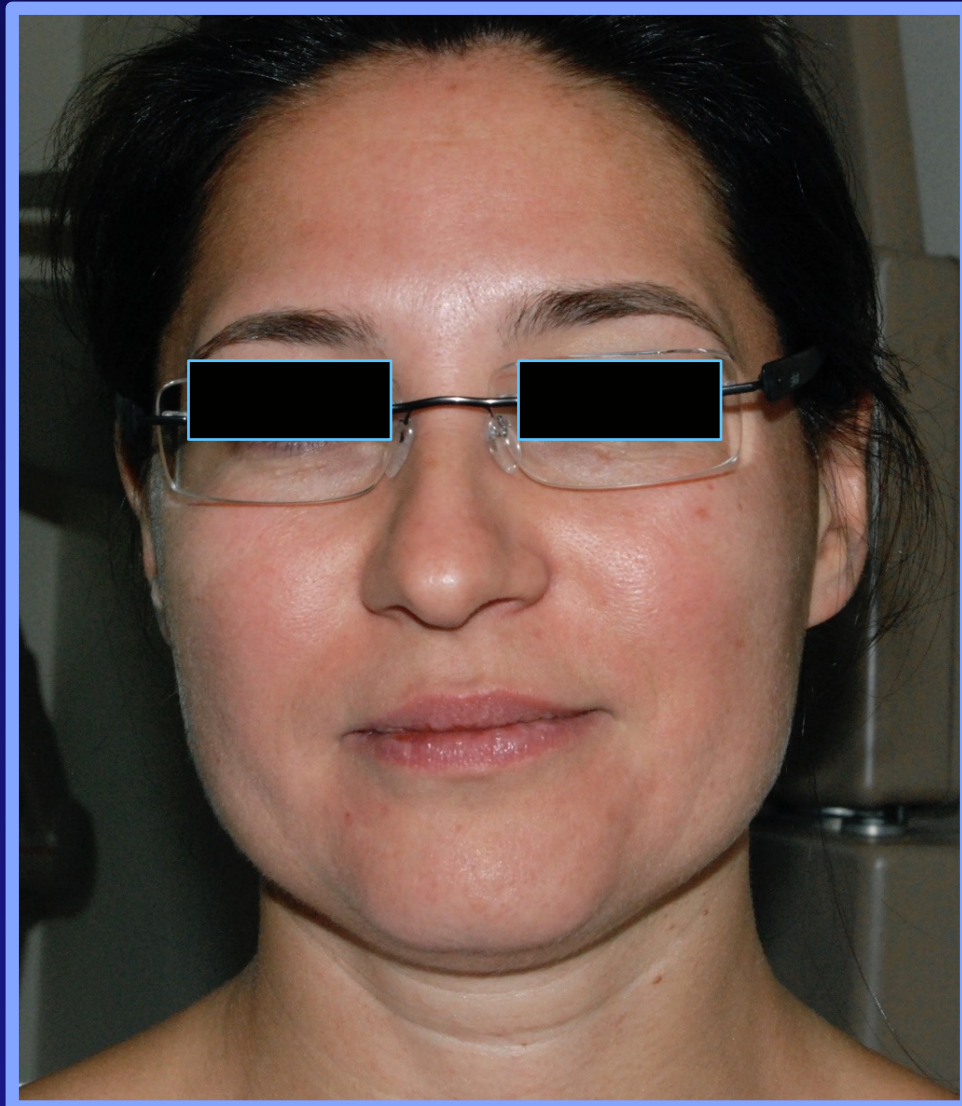# DENTAL HISTORY



The maxillary left first molar was infected with *Strep viridans*, which infiltrated the adjacent bone. Extraction did not solve the problem. The patient was in pain for 2.5 years following the extraction. Resolution came with Rife frequency treatments and injection of a Sanum homeopathic remedy to neutralize the Strep.

**Root Canaled Teeth  
and Surrounding  
Bone are Best Treated  
with Rife Frequencies**

# Dental Ovarian Cyst Connection



38 year-old Female

## Medical History:

8/03 Last child delivery performed via C-section.

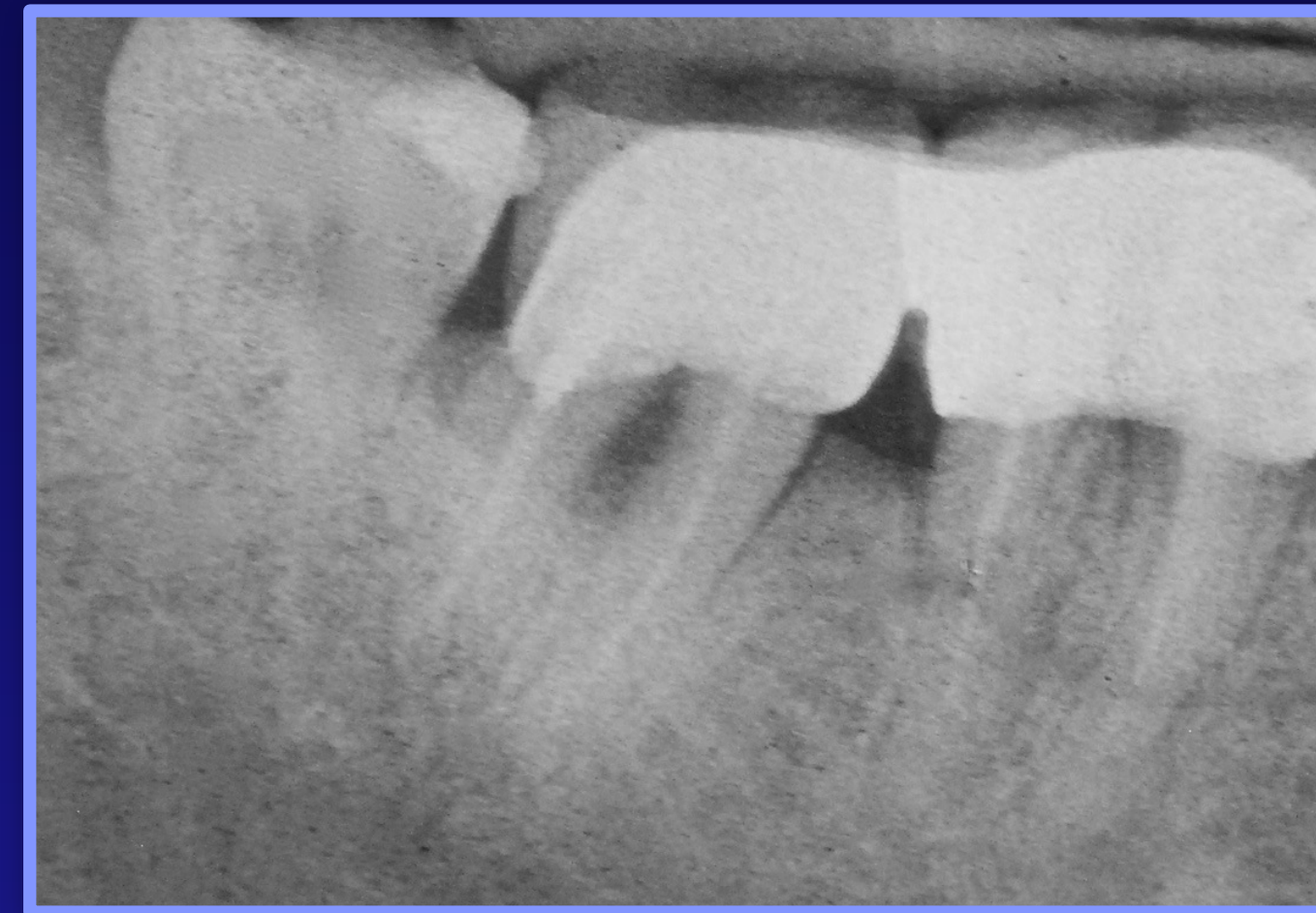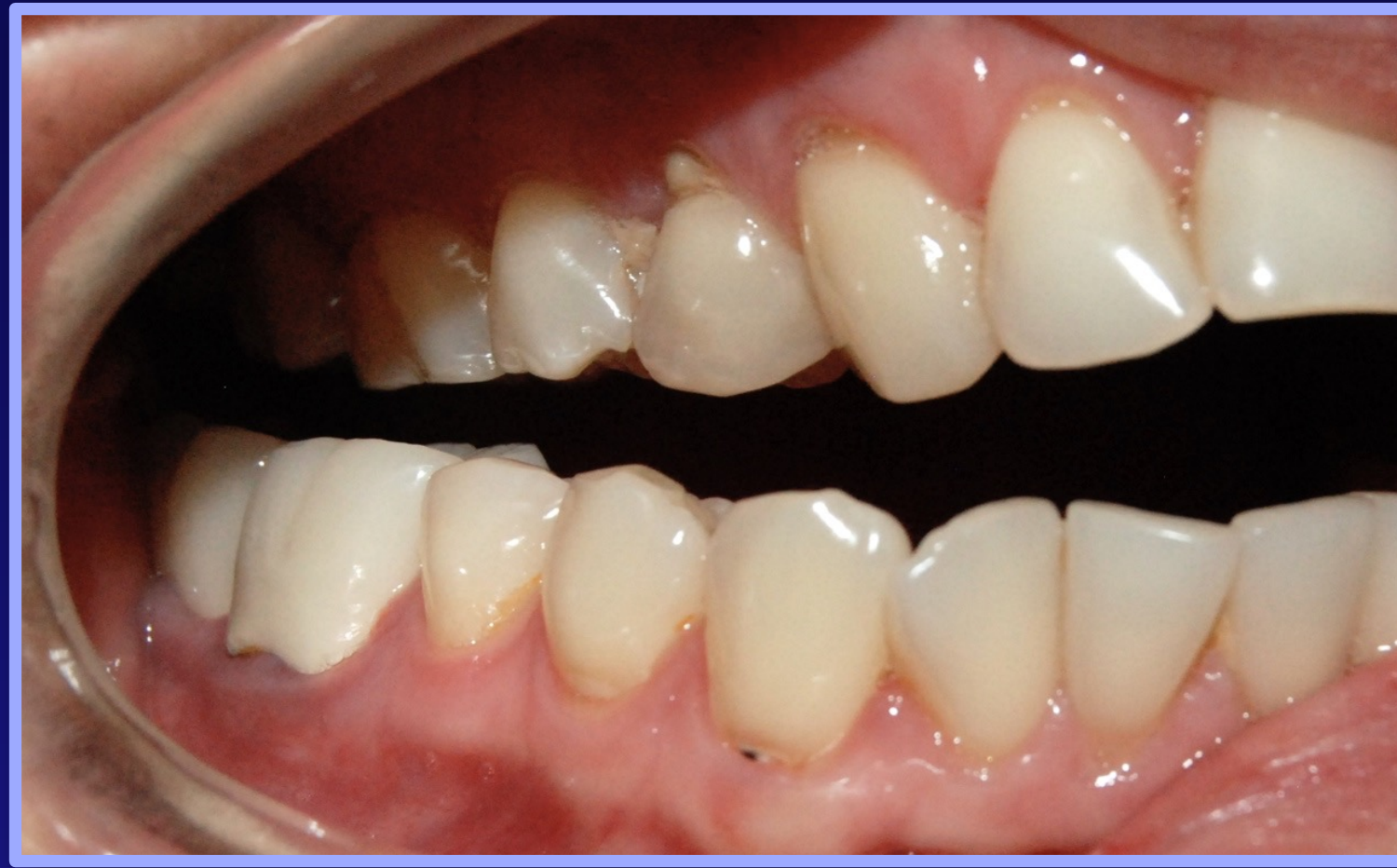Lower back pain with no history of trauma.

**Sonographic Evaluation:** Transabdominal imaging with trans vaginal views.

**Impression:** mildly complex probable hemorrhagic right ovary cyst.

In a high percentage of cases, the medical pathology is on the same side as the root canal treated tooth.

# Dental Ovarian Cyst Connection



## Dental History:

Root canal therapy performed in 2009 on mandibular right second molar.

Direct Resonance Testing revealed CMV in tooth #31 and in right ovary.

**Sonogram taken 4/11/2011**

**Impression:** Small amount of free fluid in cu-de-sac for which a follow-up study in six weeks is recommended.

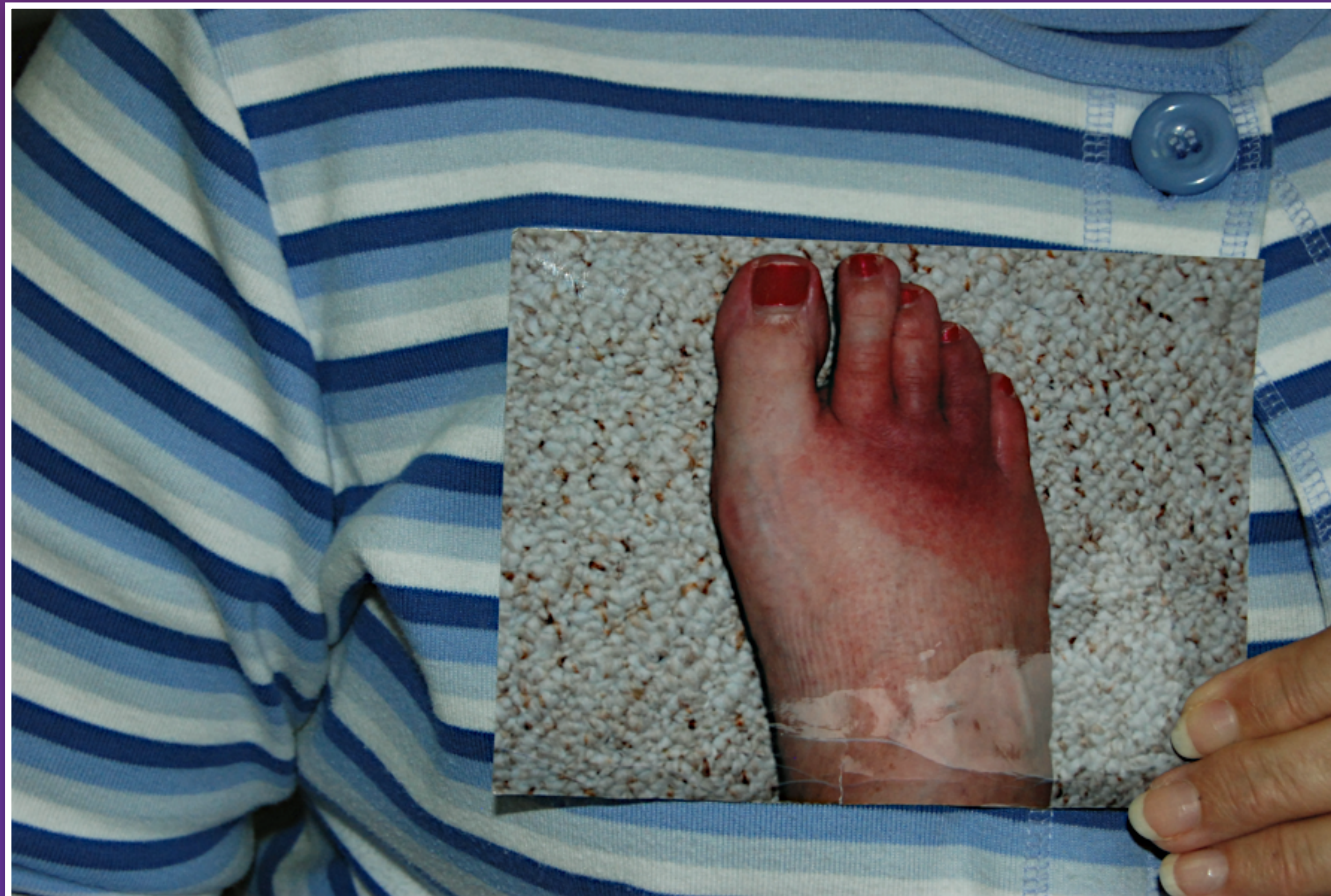**Rife Treatment:** Cyst totally resolved in three months.

# **Bell's Palsy Lyme Connection**



# Quantum Testing Approach To Diagnosing

## SPIDER BITE



**2.5 years ago (2008) patient developed Bell's Palsy soon after a spider bite. No medical diagnosis of the etiology could be made despite numerous tests.**



**Quantum Testing diagnosed Lyme in the site of the bite and left facial nerve complex. Three months Tx resolved symptoms by 95%.**



# **Oral Shingles Herpes Zoster**

# Severe Oral Pain



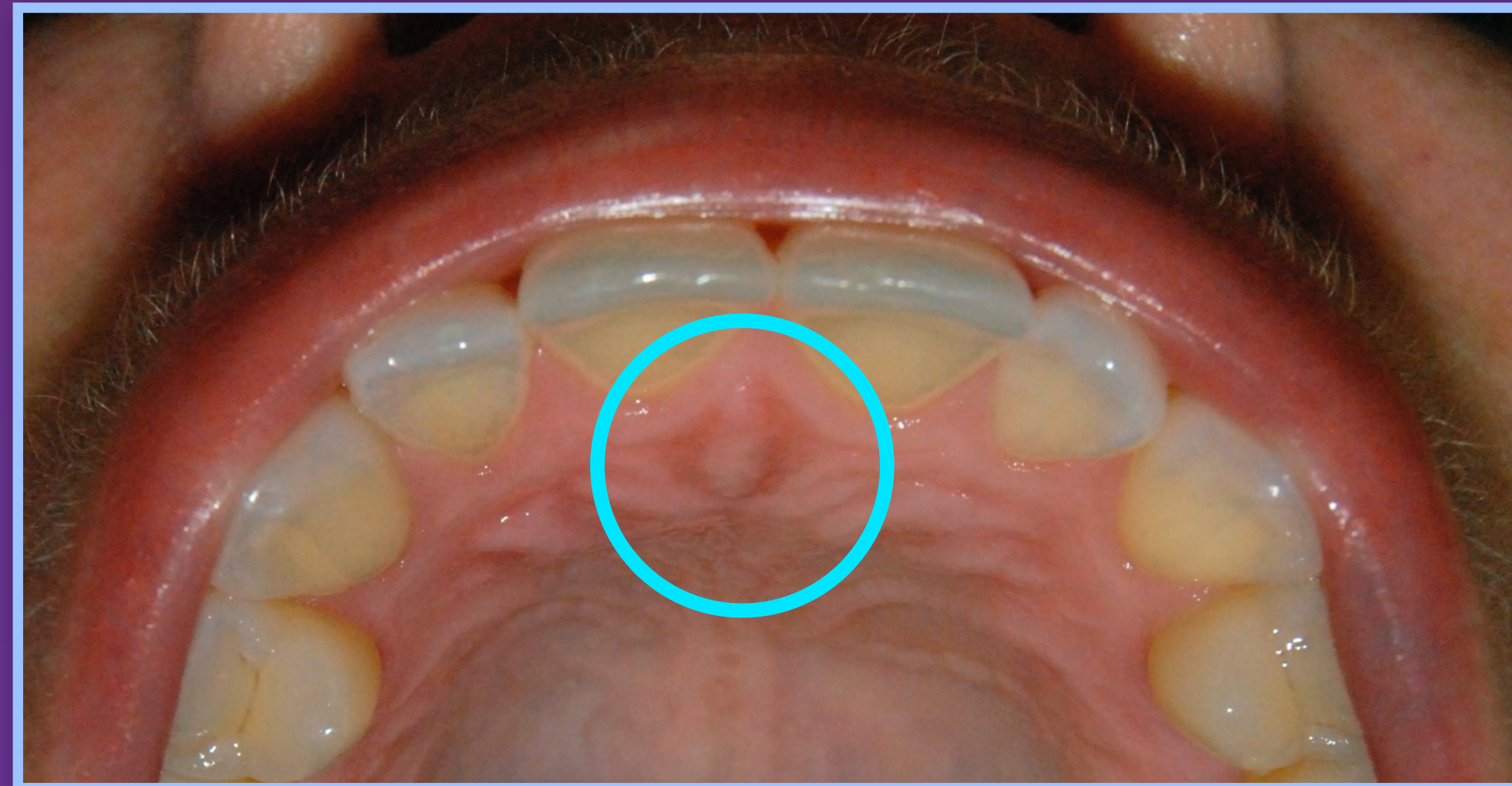
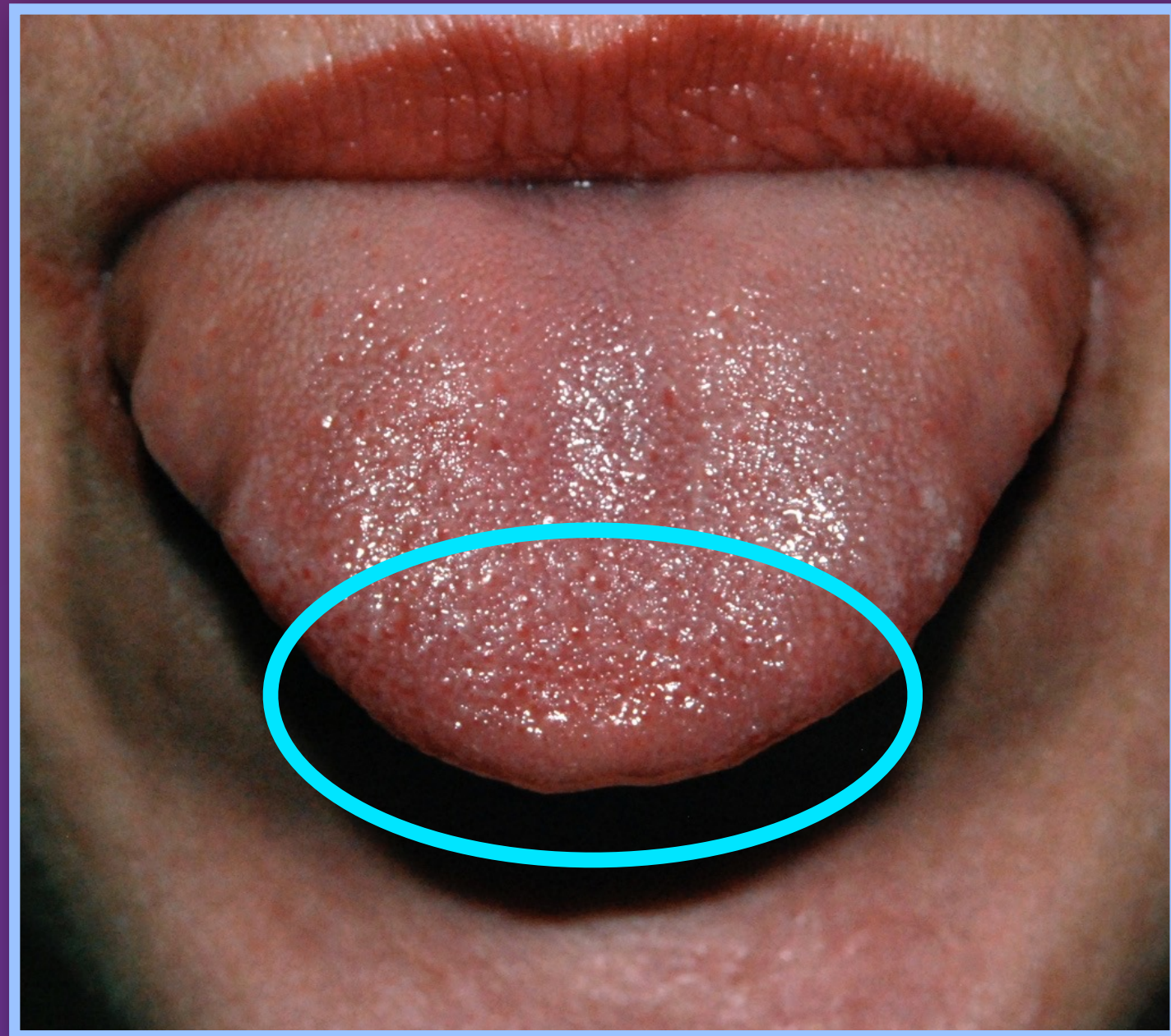## **Medical History:**

Michelle had severe pain on the tip of her tongue and incisive papillae for four months.

## **Treatment:**

All conventional Tx failed to resolve the pain.

# Severe Oral Pain



Quantum testing made the diagnosis of shingles in both areas. Homeopathic HZ (Energetix), nutrients (Alli-C, SOD, DHLA, calcium, flax oil, and Rife Generator were used to resolve the virus.

**Dental Chronic  
Atypical  
Facial Pain  
Connection**

# Chronic Atypical Facial Pain

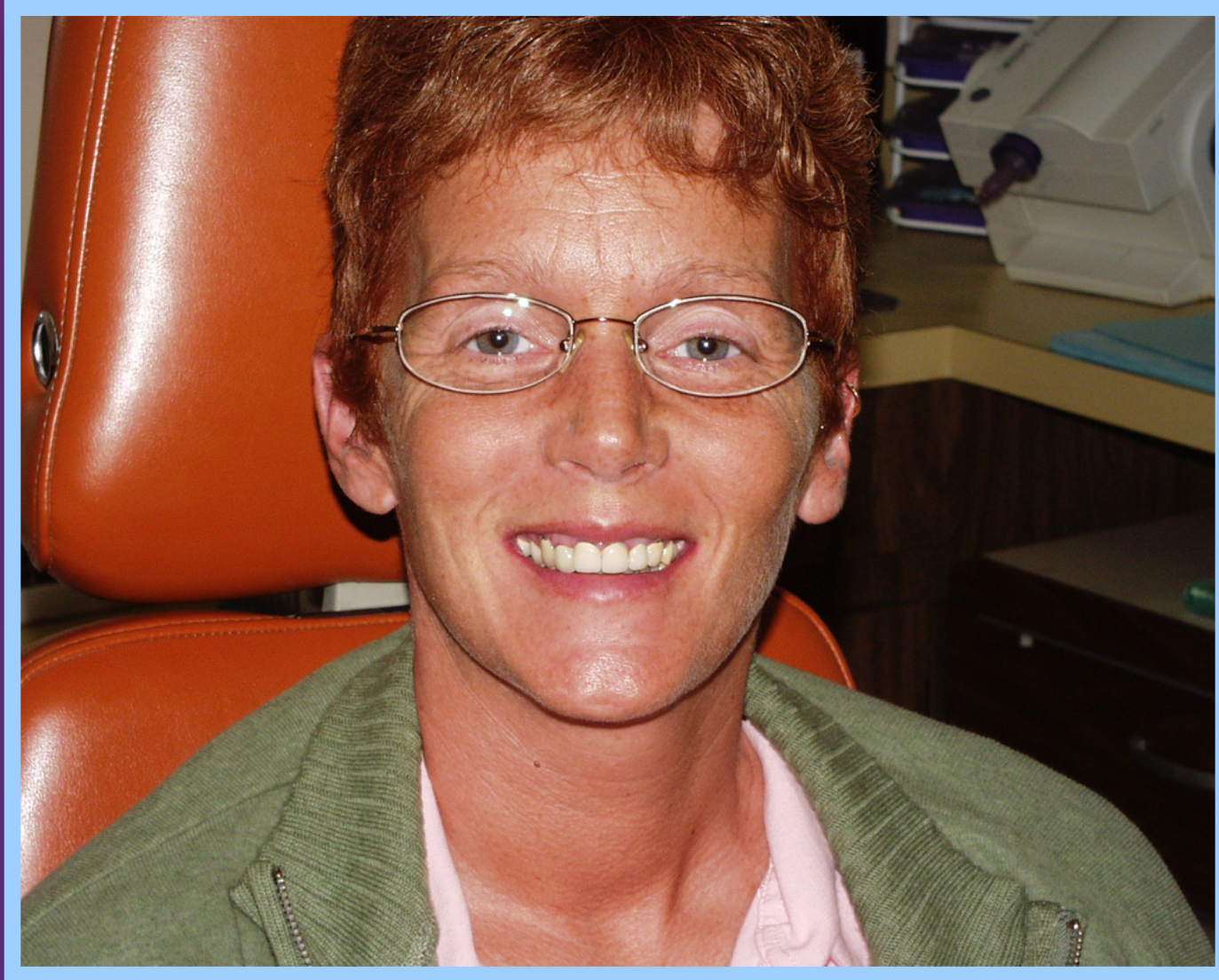

Dawn McMahon

C.C. Severe Facial Pain lower right mandibular area near canine.



# Medical/Dental History



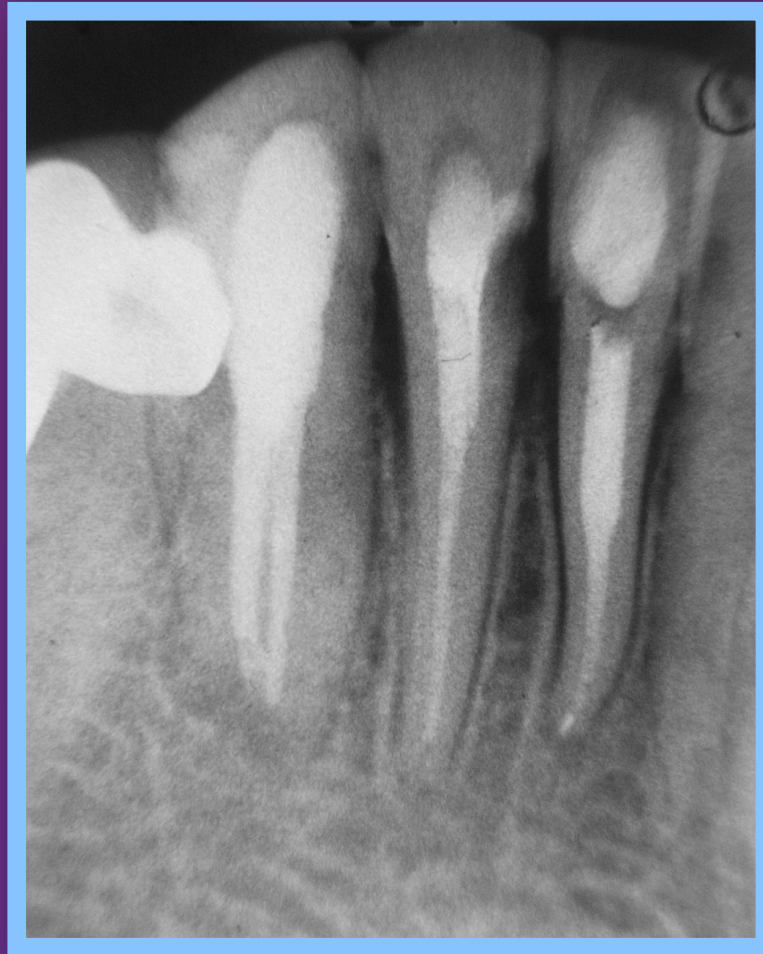Dawn McMahon

- Nerve Blocks - #27 Failed  
12/05 thru 3/06
- Root canal on #27- failed
- Root canal re-treatment- failed
- Apico- failed
- Ablation of mental nerve- Failed
- 4/06 Gamma knife- failed
- 9/06 Craniotomy (32 staples)- failed

Two and half weeks treatment with the Rife technology reduced the pain by 50%. Extraction of the lower right canine tooth totally resolved the pain.

# Common Dental Issues

## Dawn McMahon

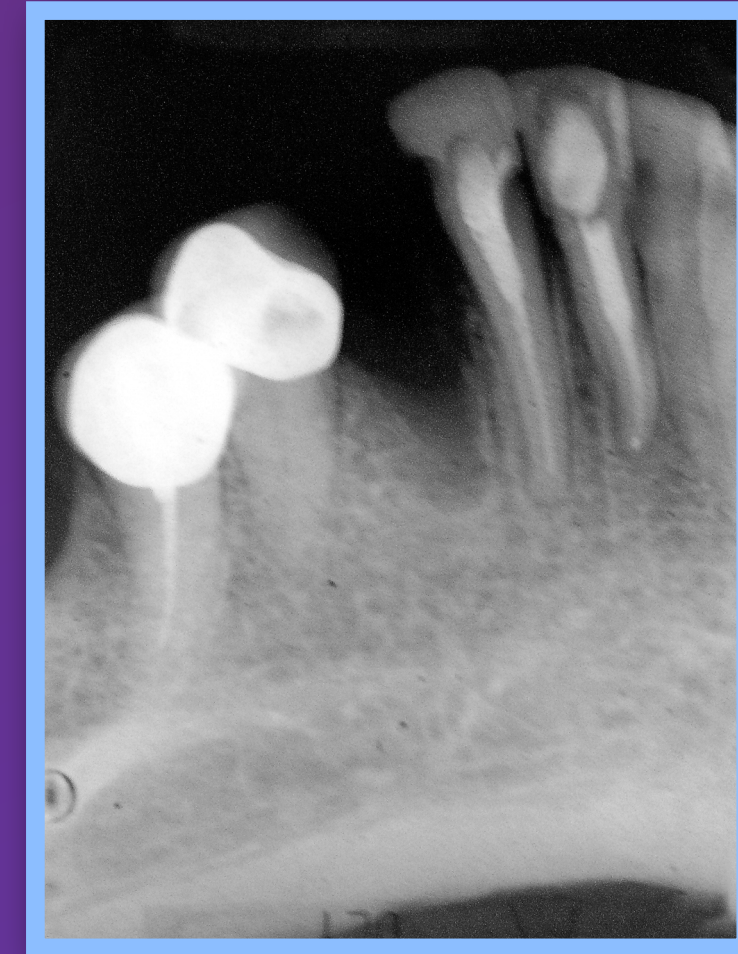

### Medical/Dental History

**C.C.** Severe Facial Pain lower right mandibular area near canine.

### Direct Resonance Testing:

- Herpes Zoster
- Herpes Simplex I



*“Modern” Dental Technology is based on Neanderthal Mentality.*