

BREAKTHROUGHS IN QUANTUM DENTISTRY & NUTRITION

A HEALTHCARE CHALLENGE

A NEW PARADIGM

Presented by

Gerald H. Smith, DDS, DNM, IMD, DHM

May 5, 2020

NEW BOOK RELEASE

Remove the “Splinters” and Watch the Body Heal

Defining the Real Cause of “Disease”
and How To Fix It Naturally



A Vibrational Medicine Approach to Healing the Body
Secrets of Life, Longevity, and Anti-Aging

Dr. Gerald H. Smith

In an era of medical deceit, telling
the truth is a revolutionary act!

Remove the “Splinters” and Watch:

Facial pain, TMJ, cancer, auto-
immune diseases, Alzheimer’s,
chronic pain, migraines, bipolar
disorder, CHF, seizures, vertigo
and many more “diseases”
DISAPPEAR !

Now available at www.ghsdoc.com

BREAKTHROUGHS IN QUANTUM DENTISTRY & NUTRITION

This slide presentation is available at ghsdoc.live

Quantum Nutrition Seminar

December 4 & 5, 2020

Hyatt Regency Toronto

Cranial Manipulation Seminar

February 5 & 6, 2021

Hyatt Regency Toronto

Seminar Brochure available at

<https://www.icnr.com/li/DWBC-2019-2020.pdf>

Free Webinar

**BREAKTHROUGHS
IN QUANTUM
NUTRITION**

**New Frontier in Nutritional Healing
Vibrationally Infused Remedies**

Details are available at ghsdoc.live

**Click to view/order products from
www.teslaenergy-tec.com**

New Technology Based on Established Truths

- The body functions like a slinky; a distortion at one end will create a distortion at the other end and somewhere in between.
- Genes DO NOT CONTROL biology.
- Cellular physiology is controlled primary by environmental factors.
- Disease is the result of a toxic terrain.
- All cancers are the same: due to hypoxia or low oxygen.
- By removing the “splinters” the body will go back to “factory default.”

Must View the Body Globally

Five major areas must be evaluated

- Cranial Complex
- Dental Complex
- Pelvic Complex
- Physiological Complex
- Psychological Complex

QUANTUM DENTISTRY

A NEW PARADIGM

THE MATRIX

Must think out side of the box to solve complex problems

CRANIAL COMPLEX

20 Years Migraine Headaches Resolved with one Cranial Adjustment

Medical History:

Two concussions

Three whiplash
injuries

Cranial adjustment:

December 2015

Alcohol was a
trigger for her
migraines



Click to View Video

Patient has not had
a recurrence in her
migraines since
2015.

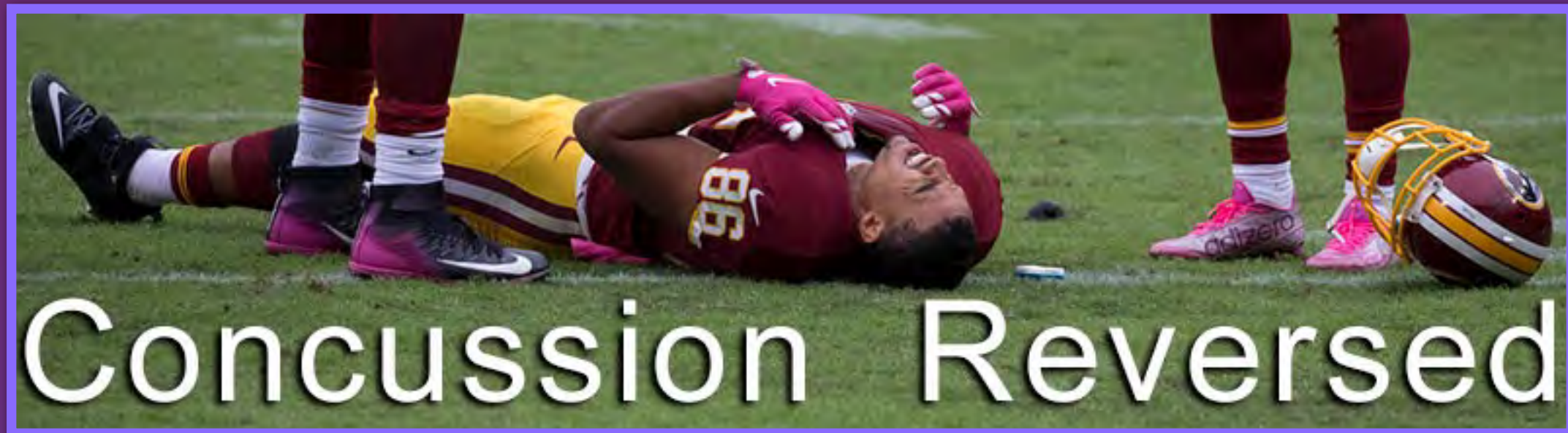Concussion



Click to View Video

In 1995 Andy was at a hockey game. Two players crashed into a glass panel at rink side knocking it out of its support rails. The glass did not break but it hit Andy in the head. He was unable to work for 4.5 months. He suffered headaches (level 3 or higher) every day for the past 21.9 years. He could tell you when it was going to rain two days before. When it rained he would crawl into bed in a dark room because the pain was excruciating.

He was seen by specialists at the Mayo Clinic, Johns Hopkins, U of P with no results. One cranial adjustment totally resolved his 21.9 year post-concussion symptoms.




ConcussionReversed.Com

Eleven case reports with testimonials

Articles and Interviews

DENTAL COMPLEX

Ian Hedley




28 years-old - Manchester, UK

Dental History:

At age 14, four bicuspids amputation, retraction orthodontics completed. Ian went from a perfectly healthy athletic 14 year-old to disabled with chronic fatigue, mental fog, head and neck tension and low back pain.

Ian Hedley




28 years-old - Manchester, UK

Dental History:

For 14 years Ian has traveled globally for answers. Various appliances, two orthodontic re-treatments, chiropractic, physiotherapy, and vitamins were used with little results.

Ian Hedley



28 years-old - Manchester, UK

Dental Dx:

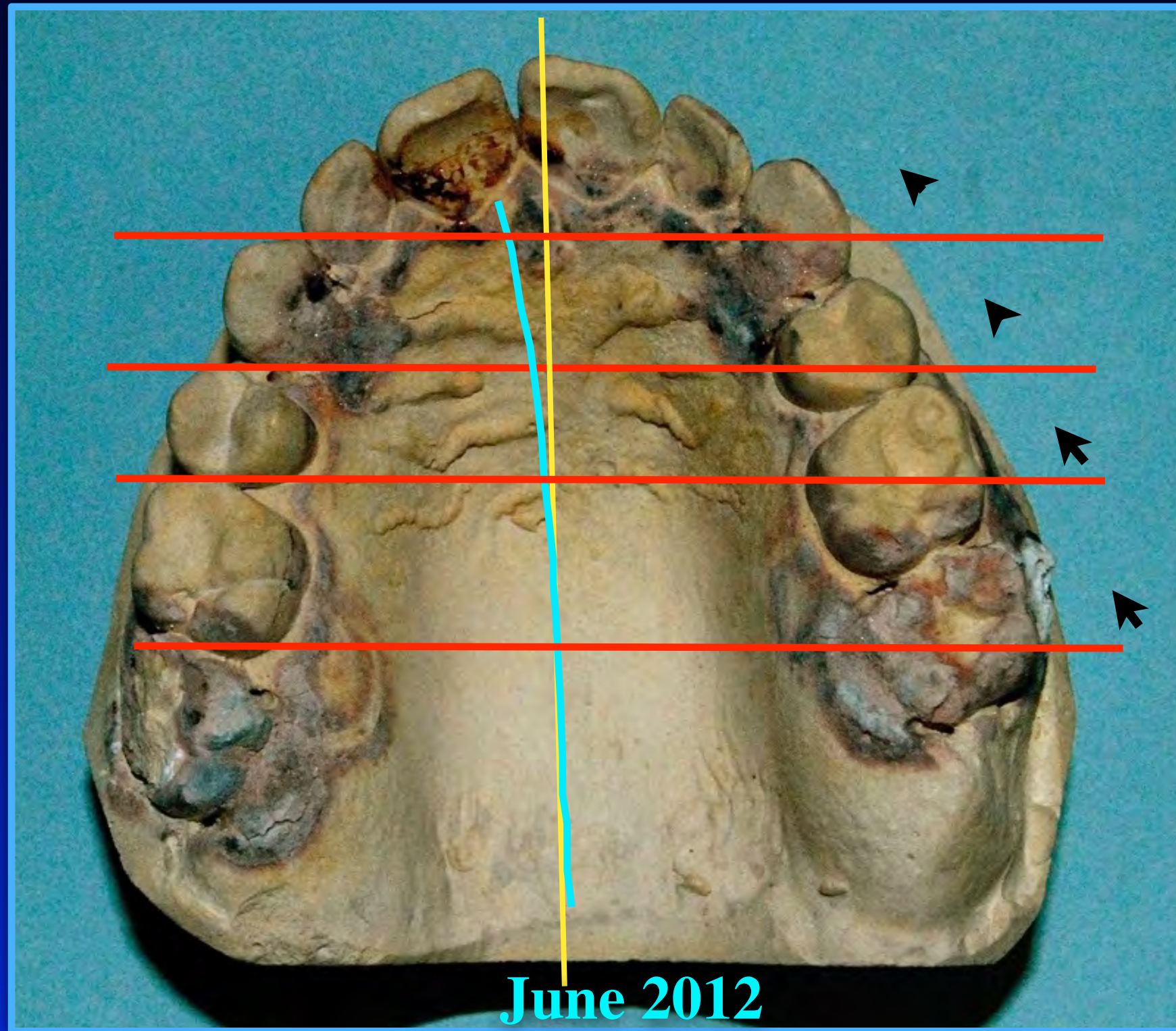
Ian's skull was compressed as a result of the 4 bicuspids extraction, retraction orthodontics and his maxillae rotated counter-clockwise twisting his dural membrane system and torquing his skull.

Flexion Lesion



Extraction and retraction orthodontics is like a head on collision. The compaction forces used to close the extraction spaces are dissipated by means of buckling and twisting of the cranium.

Counter Clockwise Rotation of Maxillae



The cranial distortion was hidden in plain view!

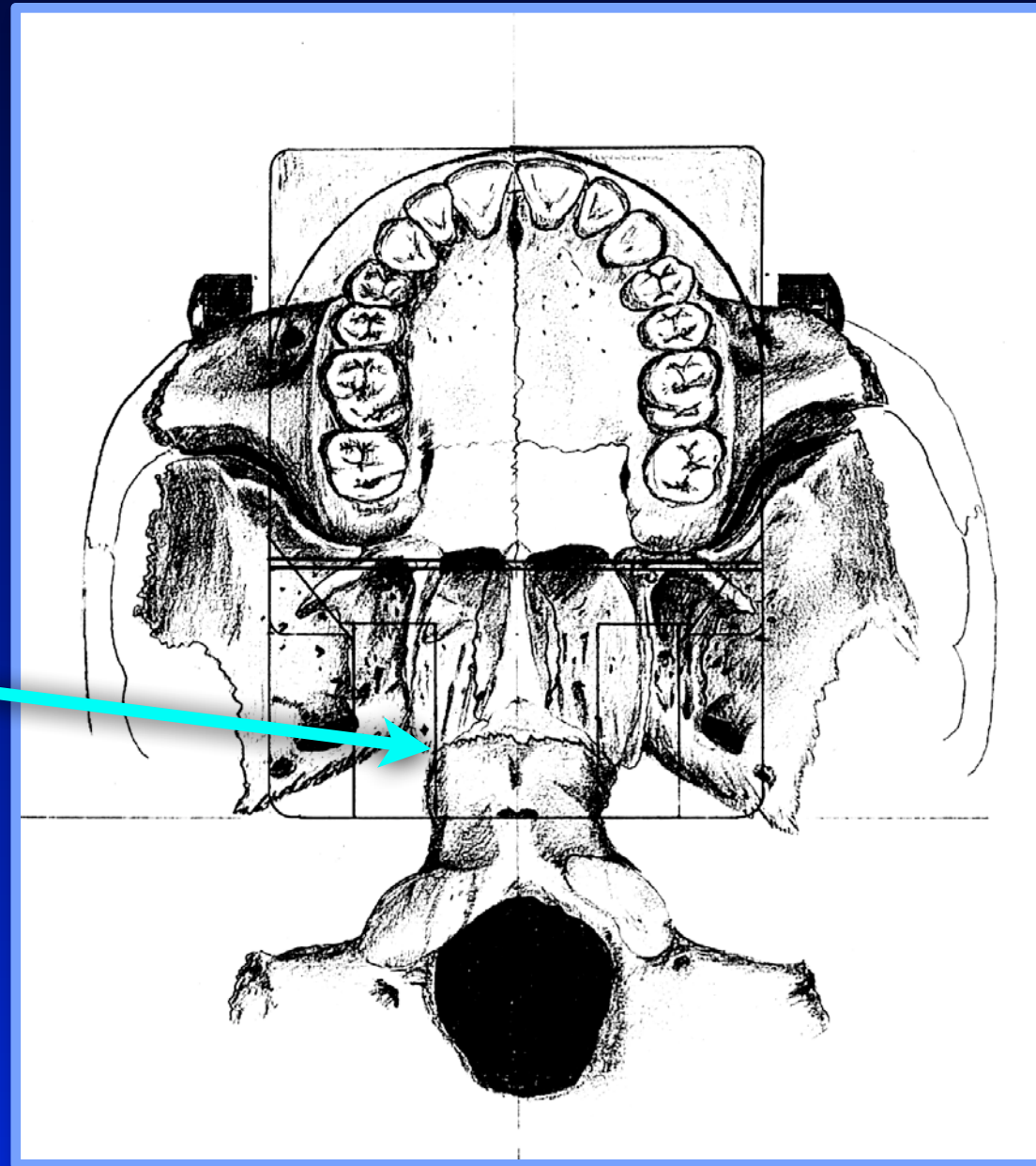
Counter Clockwise Rotation of the Toilet



The toilet distortion is hidden in plain view!

Functional Significance of the Maxillae

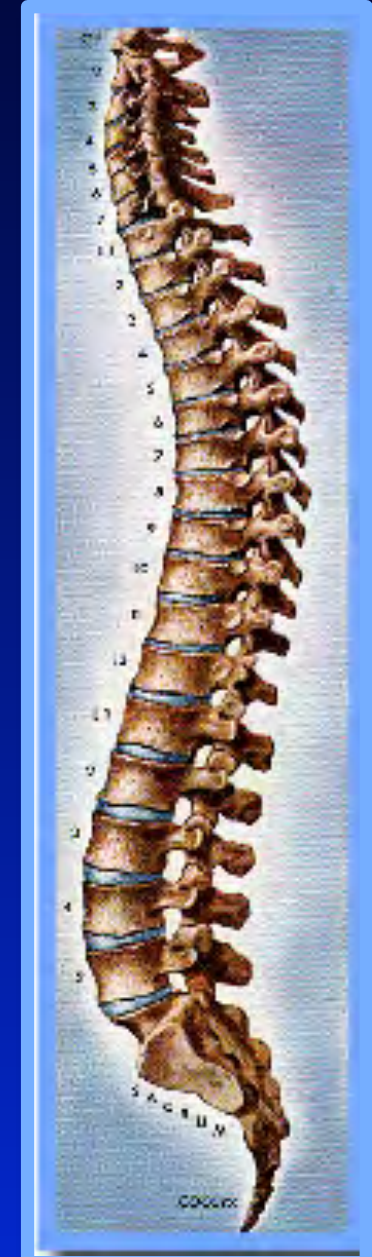
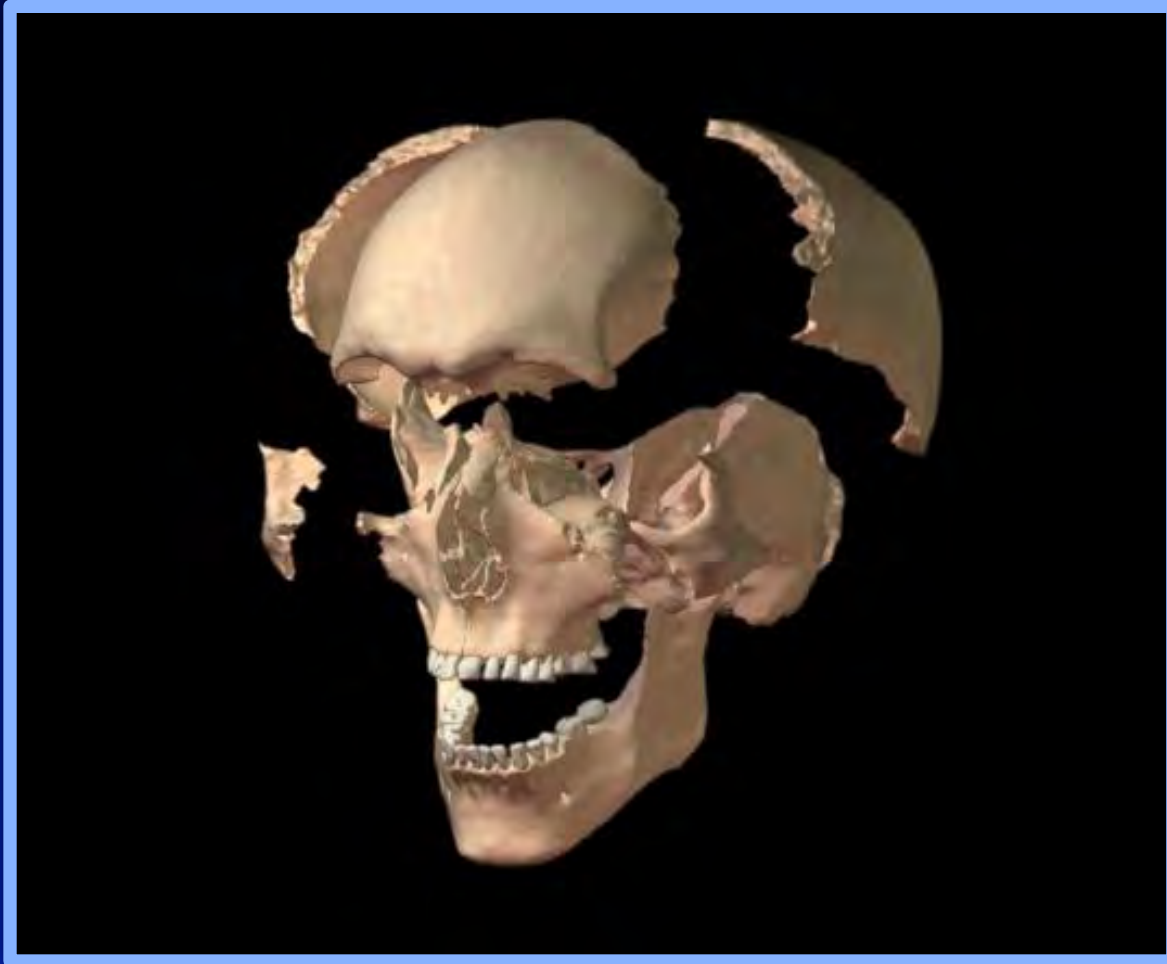Sphenobasilar
Symphysis



Drawing by Dr. James Carlson
Reproduced with permission

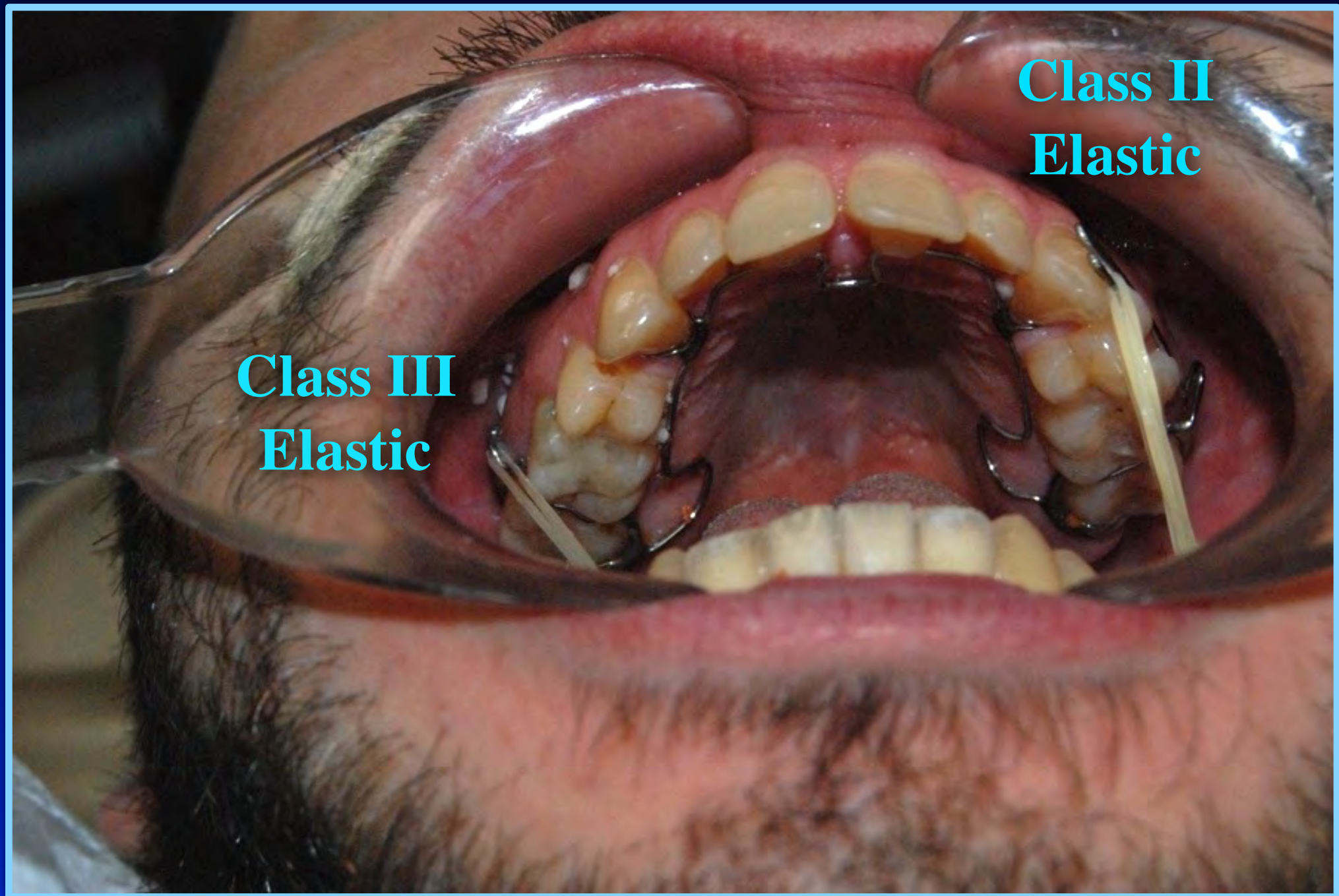The maxillae represents the anterior 2/3 of the cranial base.

Impact of a Twisted Dural Tube



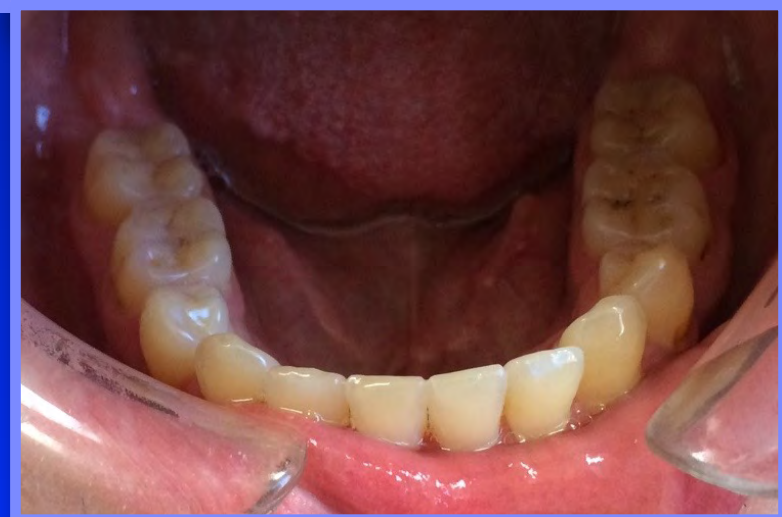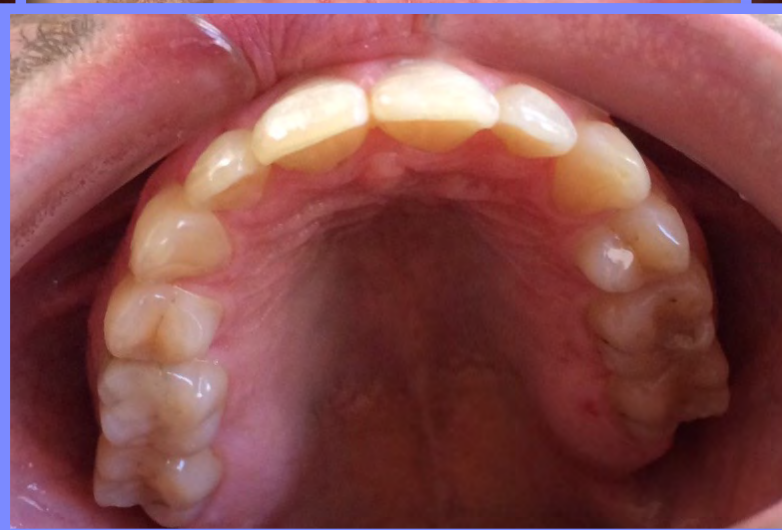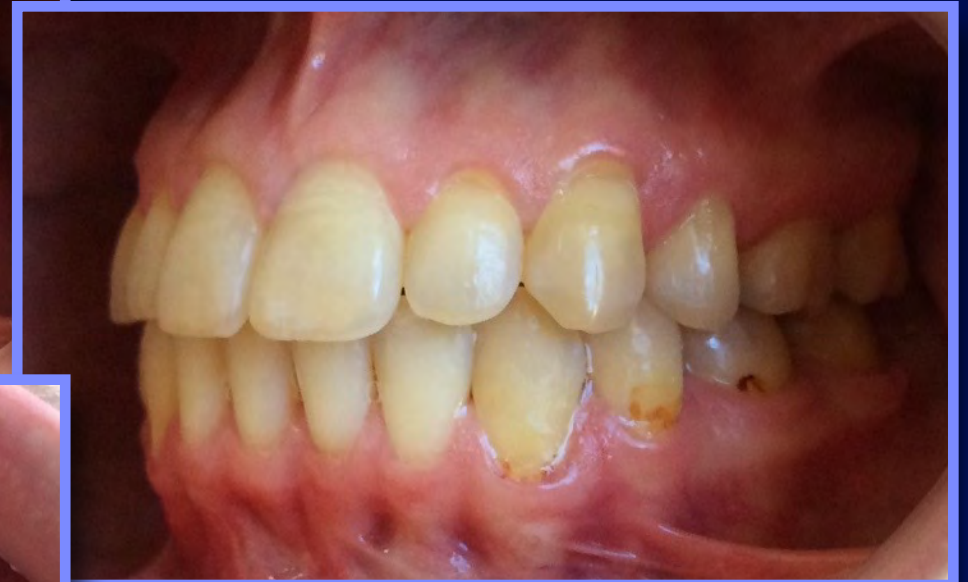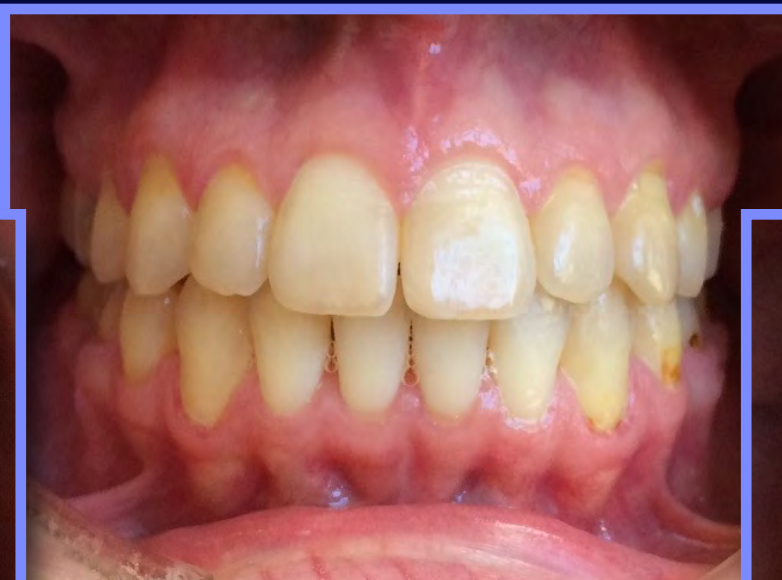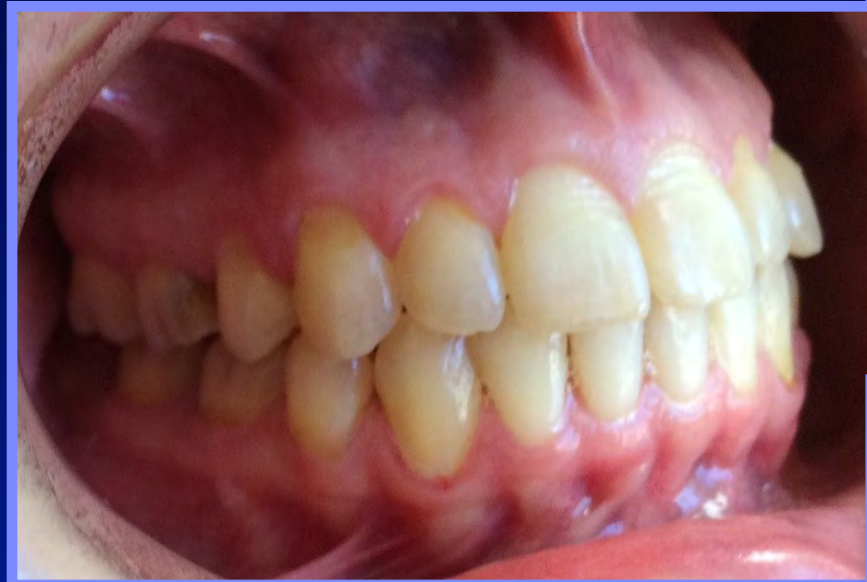When the skull distorts, it translates into a twist down the entire spine and dural tube affecting the central and autonomic nervous systems.

Tx: Expansion + Clockwise Rotation



June 4, 2012

Completed Case



The key to successful Tx was defining the counterclockwise rotation of the maxillae.

It is more important to achieve occlusal cranial balance than establishing a class I molar relationship or getting the mid-lines straight!

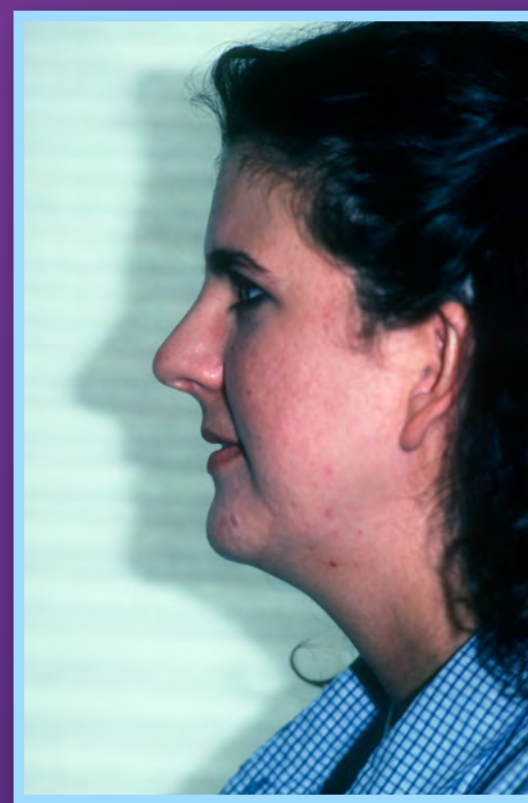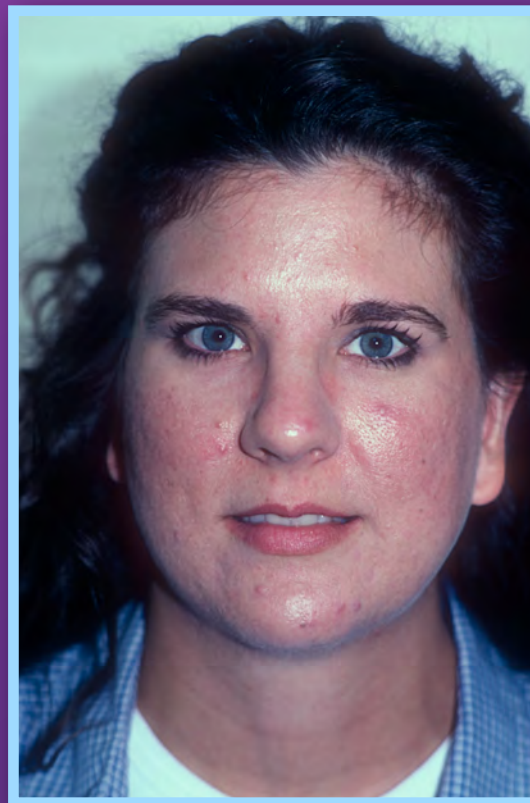Ian Hedley's Testimonial

Ian is totally pain free.
He graduated from
dental school in the
UK and moved to
Australia where he
opened up a practice.




Click to View Video

Four Bicuspид Amputation Retraction Orthodontics is Anatomically and Physiologically Destructive




Debbie Hosé

Robert Ellis



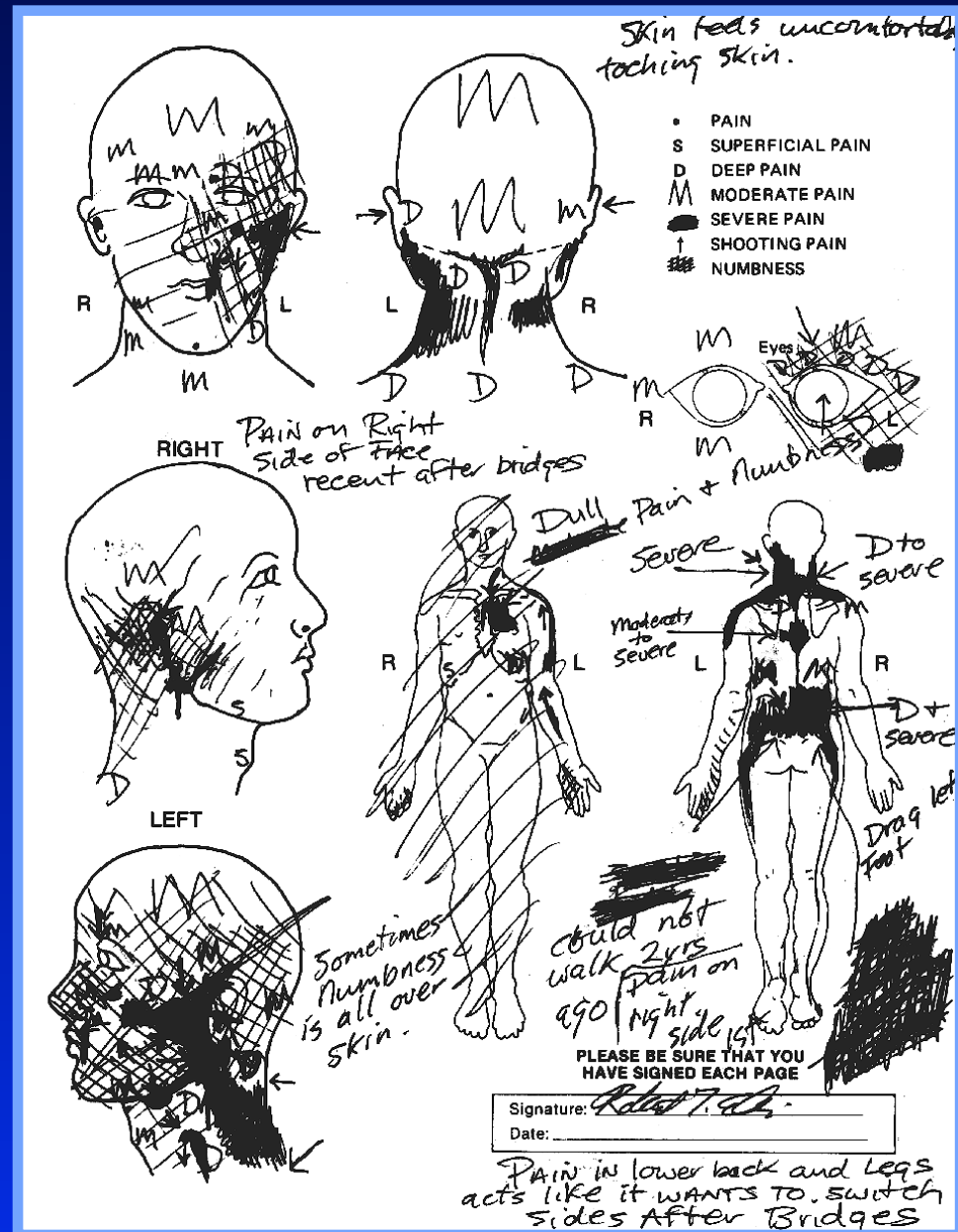
Sympathetic Dominant

**6 Months
ALF
Treatment
and
Nutritional
Support**



Balanced ANS

TMJ Diagnostic Record

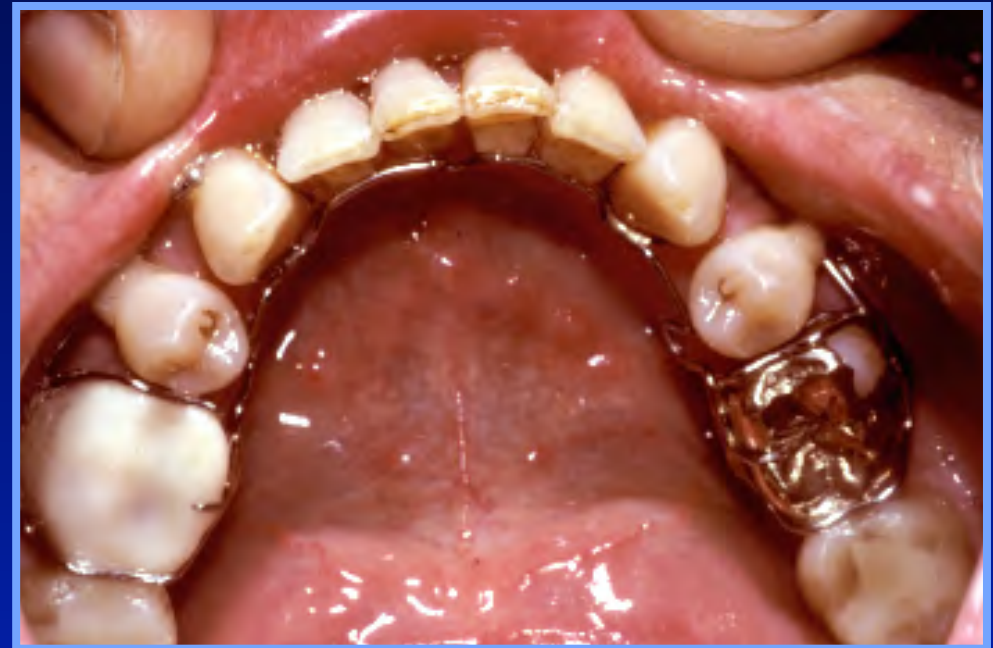
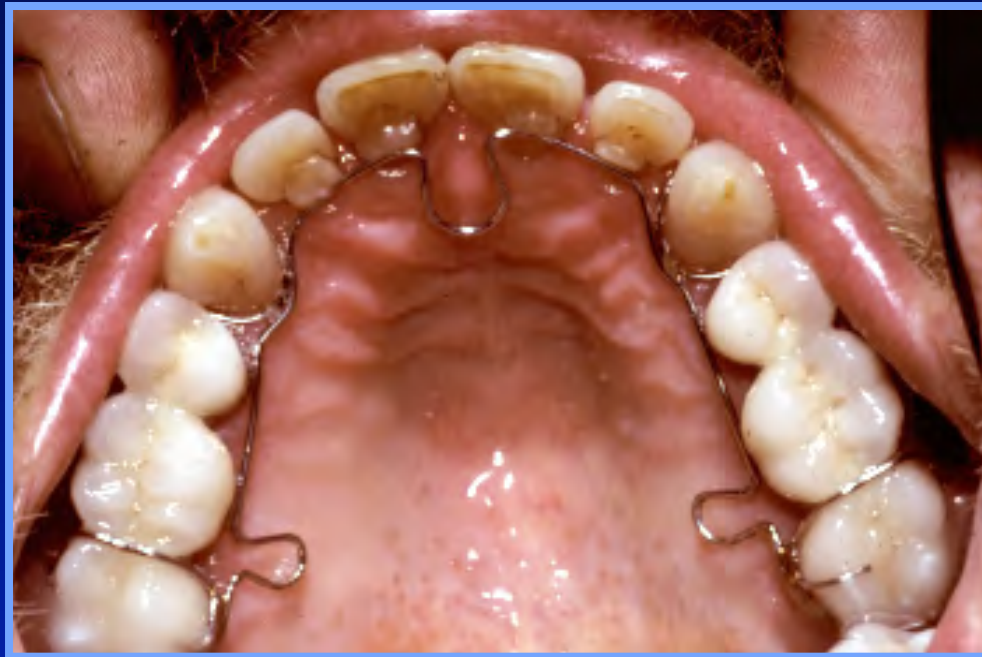
Robert Ellis

Highlights

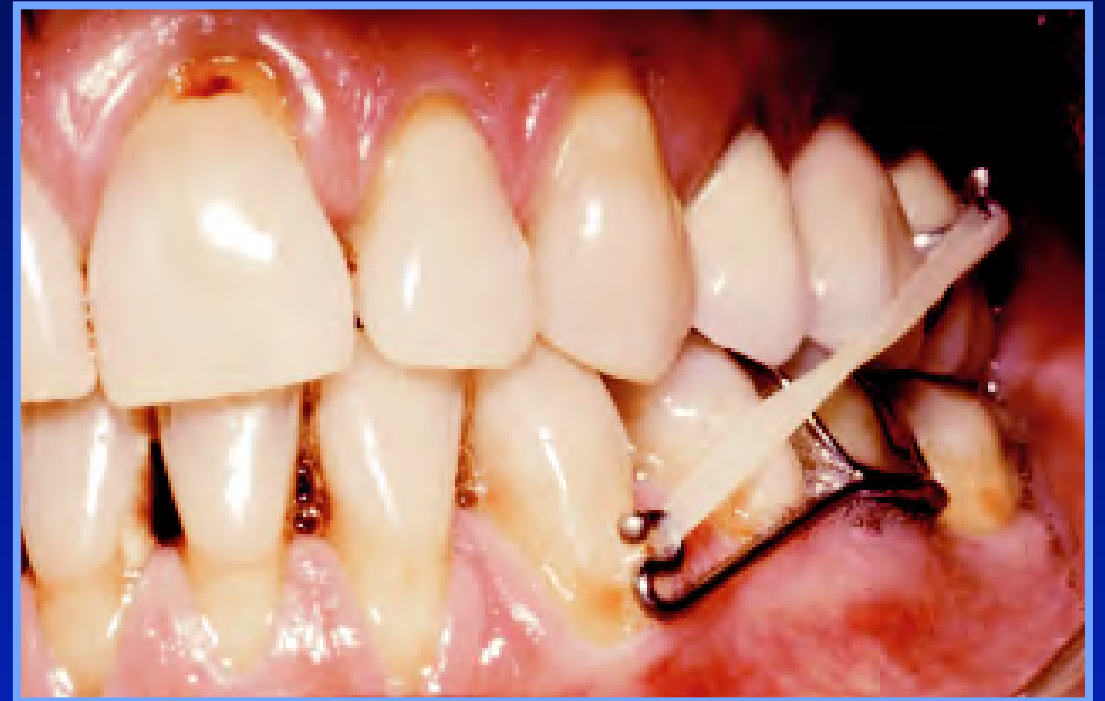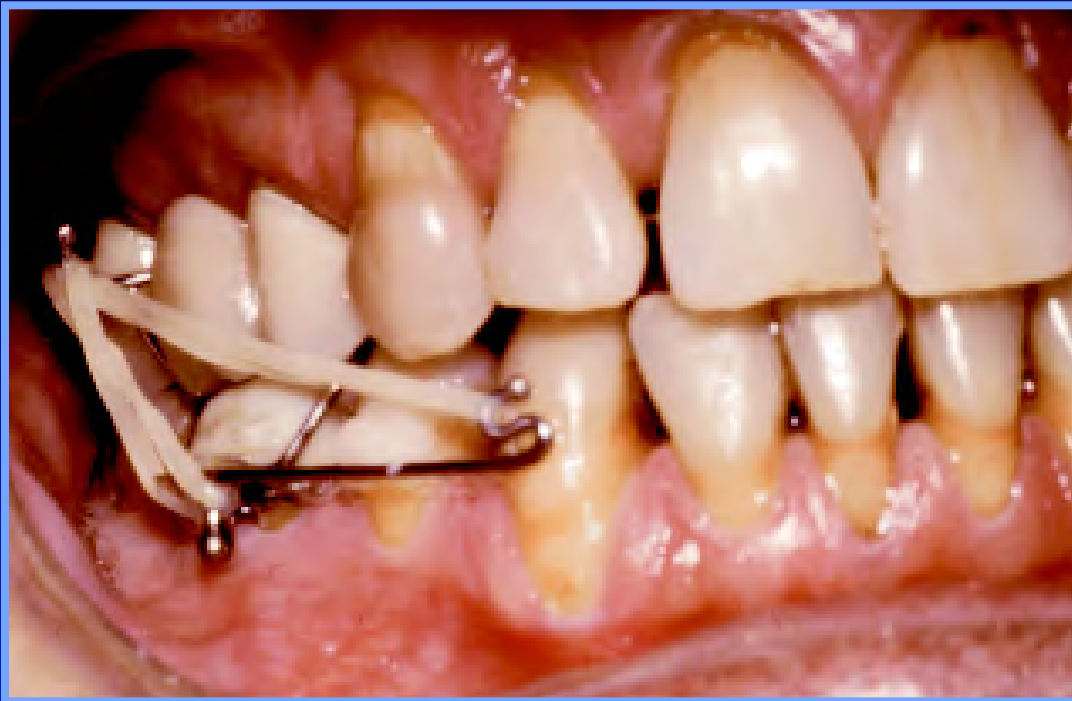- Day braces place patient (age 12yrs) became dysfunctional: lost coordination and mental acuity.
- Pain on right side of face occurred soon after two three unit maxillary bridges placed.
- Following bridge insertion, pain in lower back and legs felt like it wanted to switch sides.
- Could not walk two years ago.
- Moderate to severe pain and numbness over entire body.

Robert Ellis




Treatment objectives are to correct the cranial lesions, level and disimpact the maxillae. Opening up the bicuspid spaces are only necessary to decompress the mandibular condyles.

Robert Ellis




Class III Elastics to disimpact the maxillae and vertical elastic to correct a high right sphenoid.

Robert Ellis



Sympathetic Dominant

**6 Months
ALF
Treatment
and
Nutritional
Support**




Balanced ANS

PELVIC COMPLEX

Full Denture Lower Back Pain Connection

Denture Lower Back Connection

Dental/Medical History - 2015



Nate's poorly fitting full dentures were 15 years-old and accompanied by sore gums.

He experienced right thigh pain for 10 years and lower back pain for 20 years. His chiropractic adjustment did not hold.

When chiropractic adjustments do not hold, invariably there is a malocclusion problem.

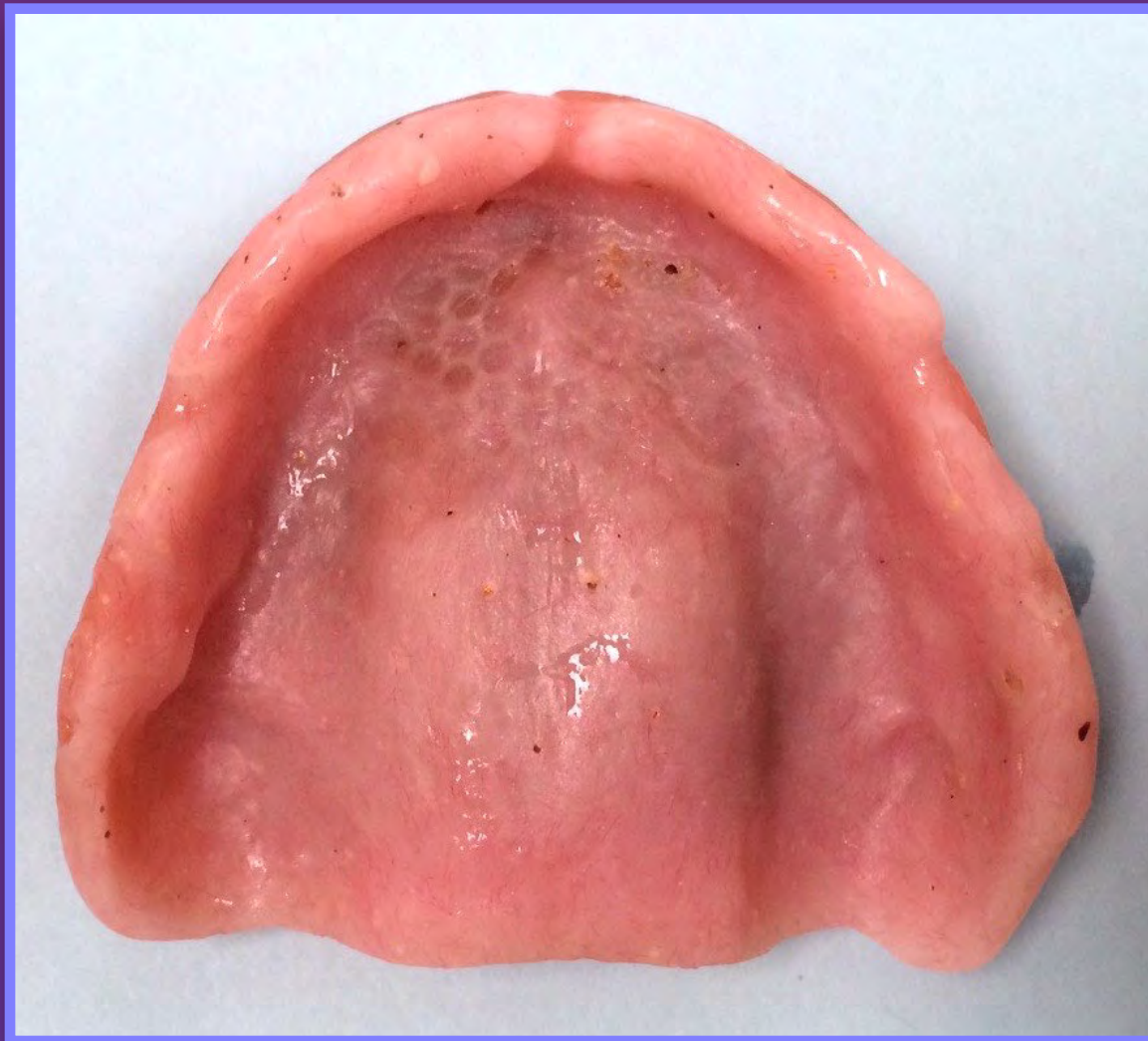
Denture Lower Back Connection

Treatment - 2015

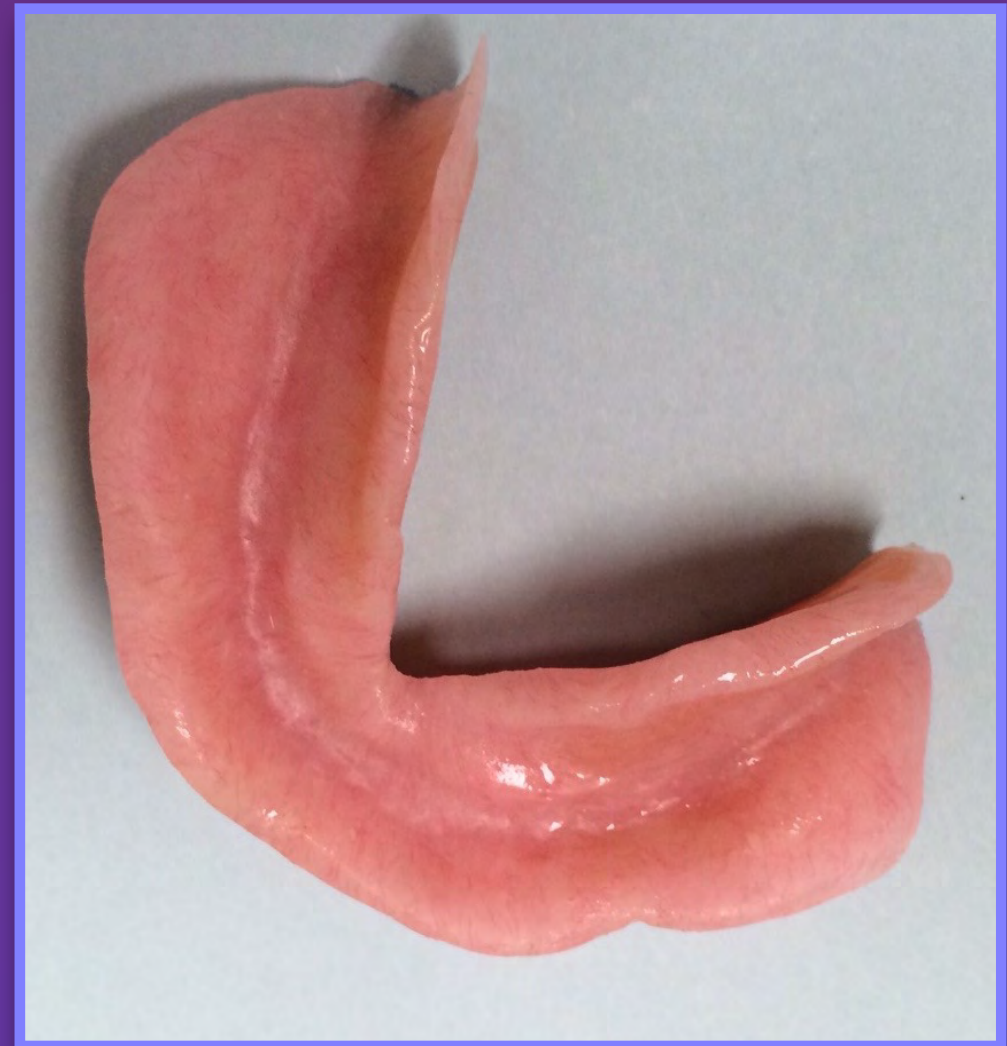1. Cranial adjustment
2. Reline maxillary denture to stabilize the cranial bones
3. Reline mandibular denture to increase vertical height
4. Placed patient on calcium lactate and Linum B6 to treat the sore gums
5. Vitamin C to repair tissue and support the adrenals

Denture Lower Back Connection

Treatment - October, 2015



Maxillary denture - soft reline



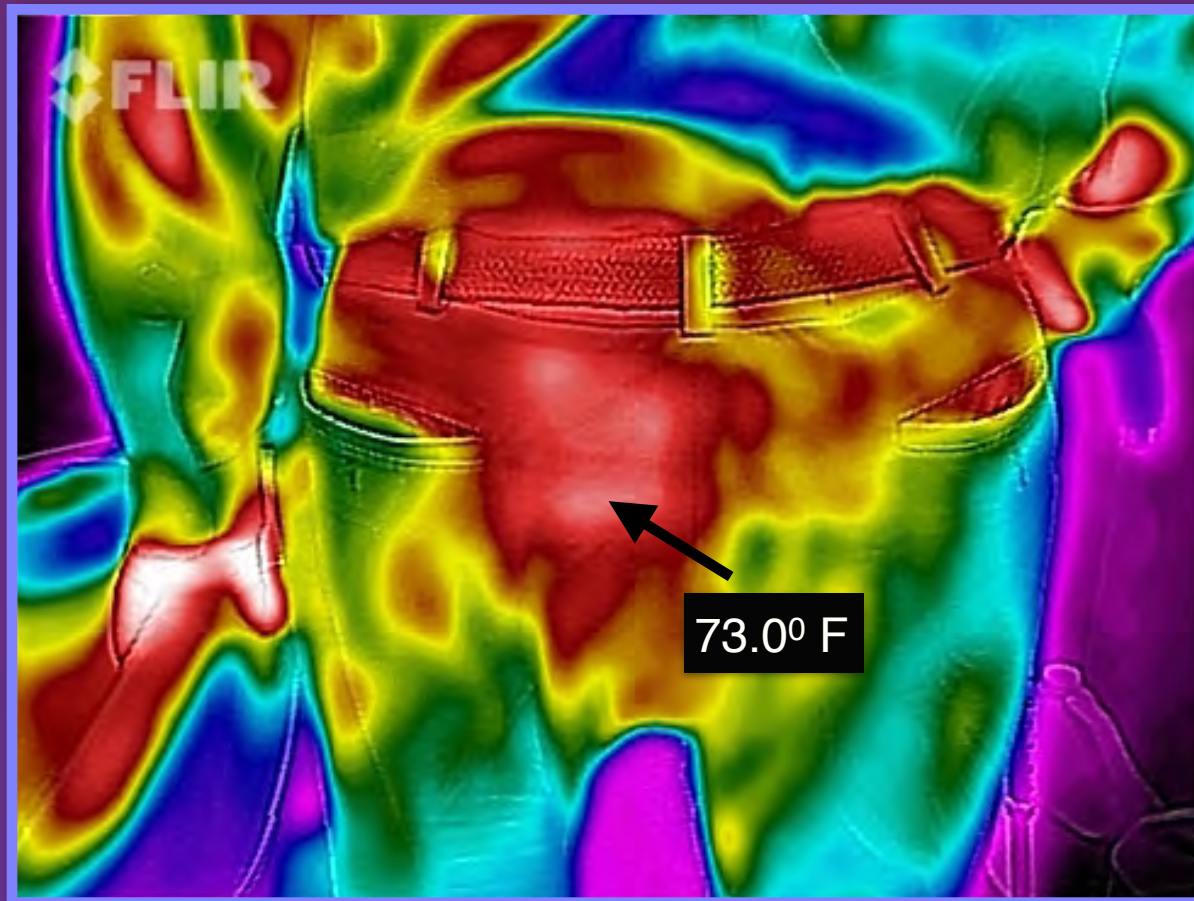
Mandibular denture - soft reline

Denture Lower Back Connection

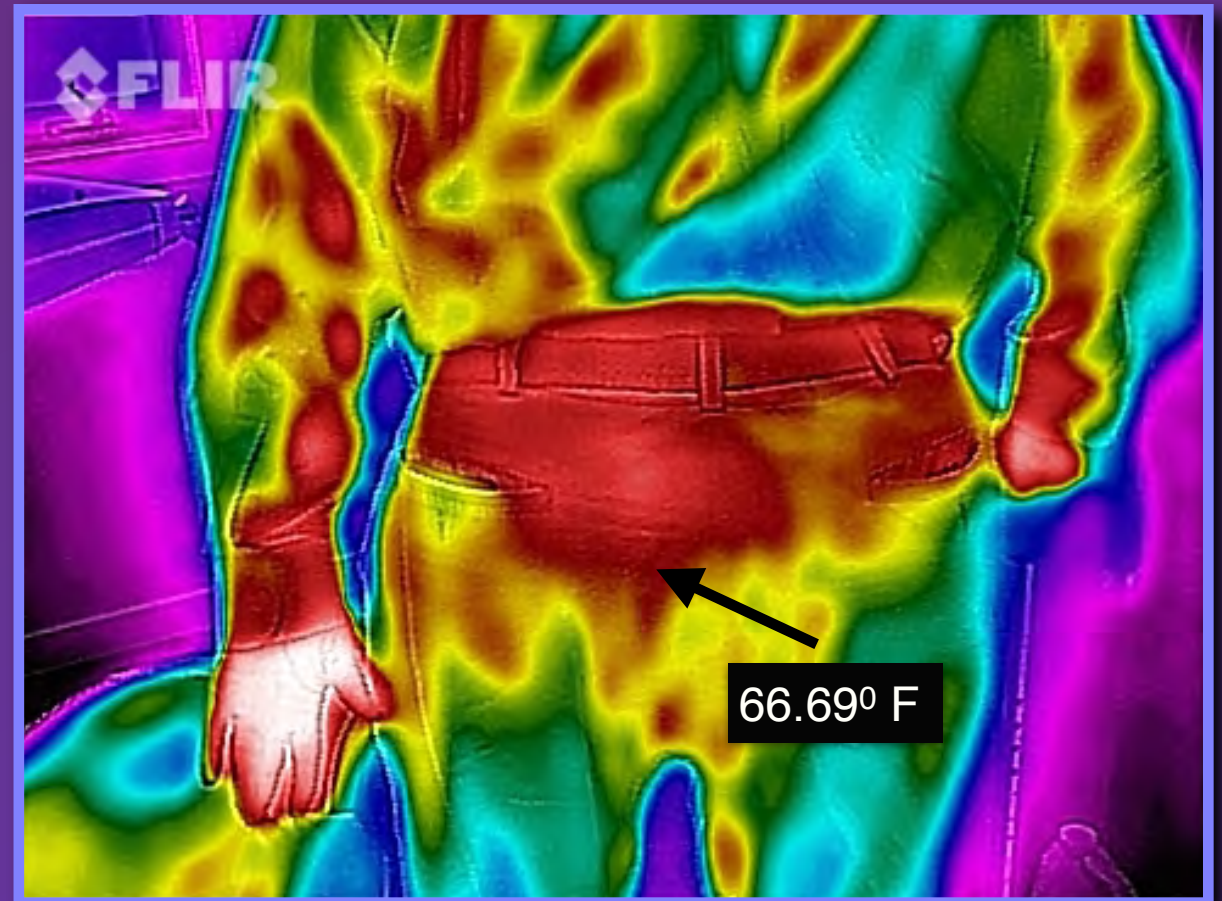
Treatment Progress - 2015

1. Following the first visit, the patient immediately stated that his 10 years of right thigh pain totally resolved.
2. Two days after the first visit patient returned and the lower denture was again relined to provide additional vertical height. Immediately following the procedure, the patient stated that his 20 years of lower back pain was 90% reduced.
3. Following the third visit the patient stated that his dentures never felt so comfortable.

Digital Infrared Thermal Imaging - 2015



Pre-Tx



Five Minutes Post-Tx
6.31° F drop in temperature

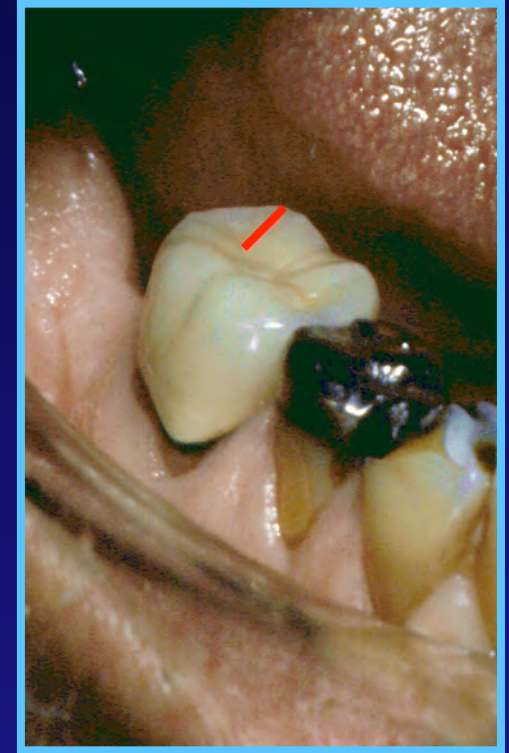Dental Low Back Pain Connection



Age: 62-year-old

Date: December 5, 2000

Occupation: Engineer



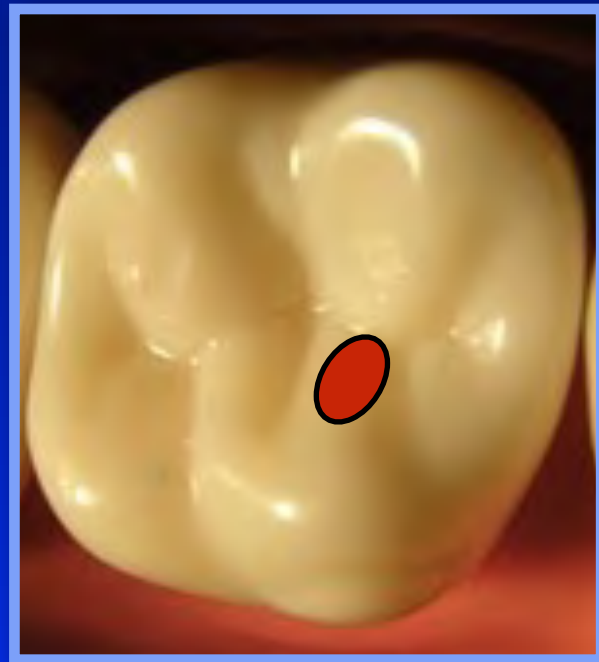Chief Complaints:

1. Constant low back pain for 8 years - Started day the lower right first molar crown was cemented.
2. Tx : Neuro Occlusal Adjustment - Low back pain disappeared immediately. Has been pain free since 2000.

Low Back Pain Due to an Occlusal Interference



Bob had a fixed three unit dental bridge placed many years ago and had no pain or discomfort associated with the work. For the past three weeks he has been getting physical therapy for a flair up of his back pain. The physical therapy did not result in any relief because it was not addressing the core issue.



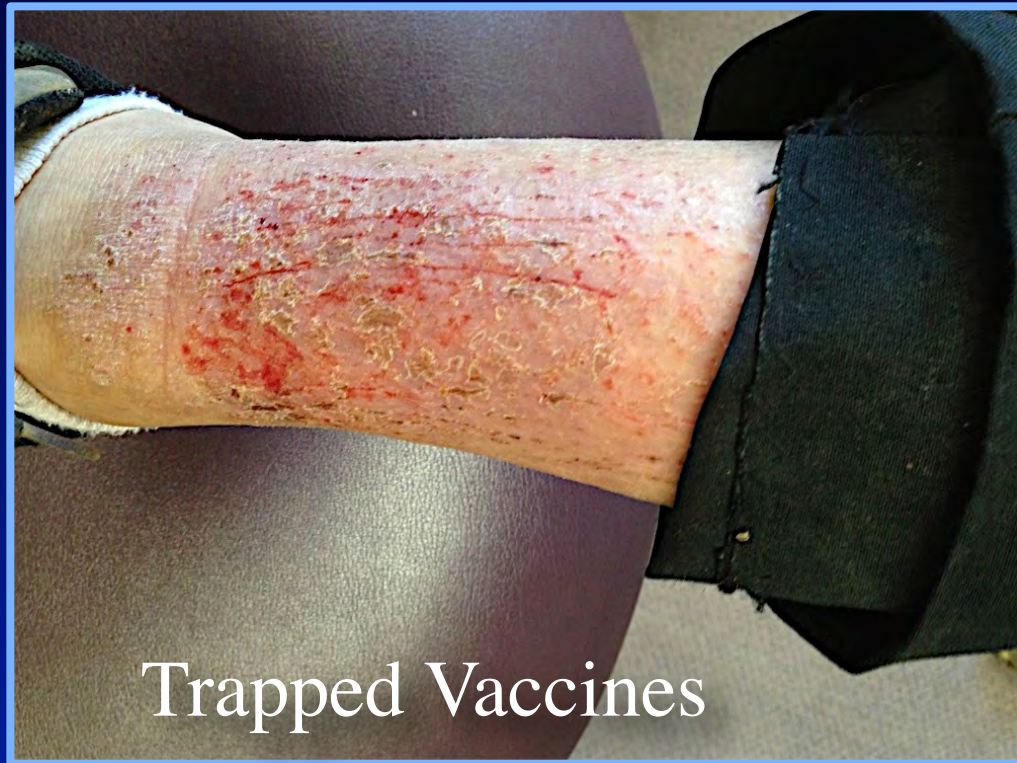After adjusting the minor interference on his bridgework, Bob was instructed to walk down the hallway. When he returned he made the comment that 98% of his back pain disappeared.

QUANTUM NUTRITION

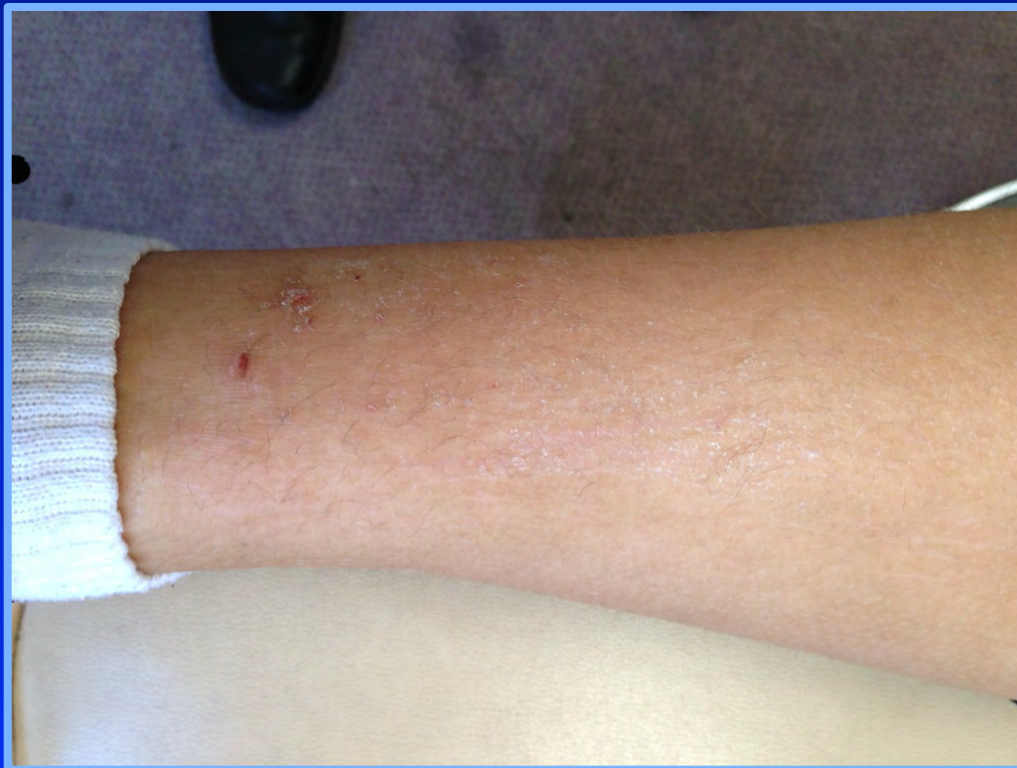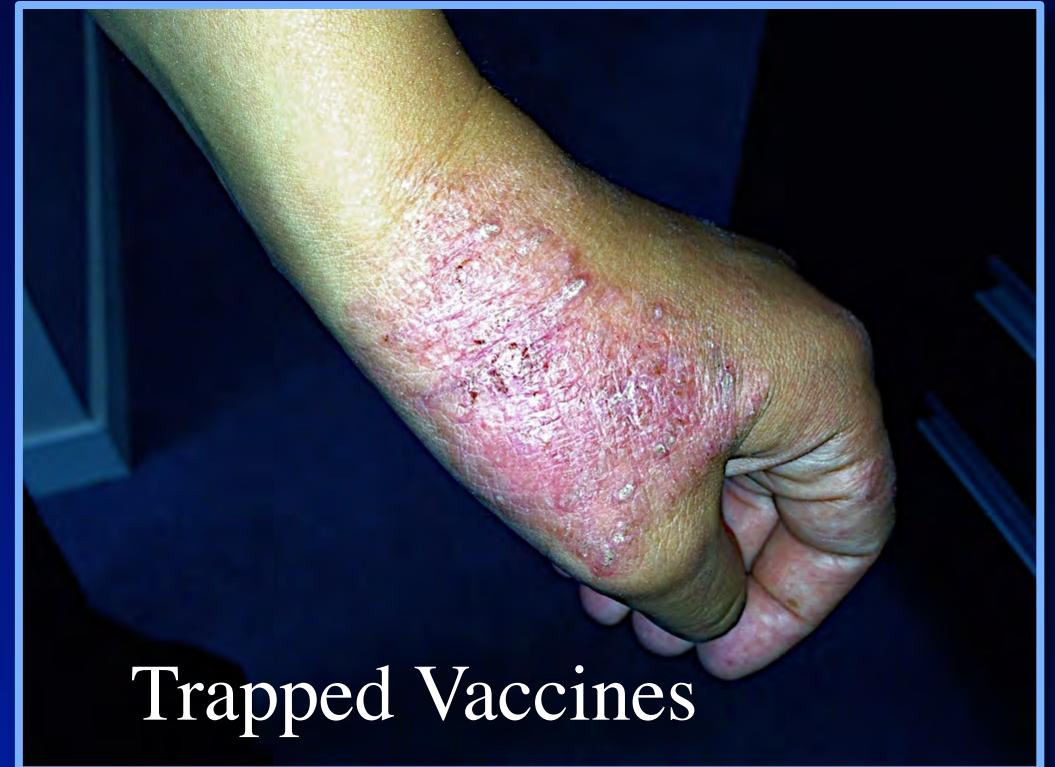A NEW PARADIGM

DEFINE THE ROOT CAUSE

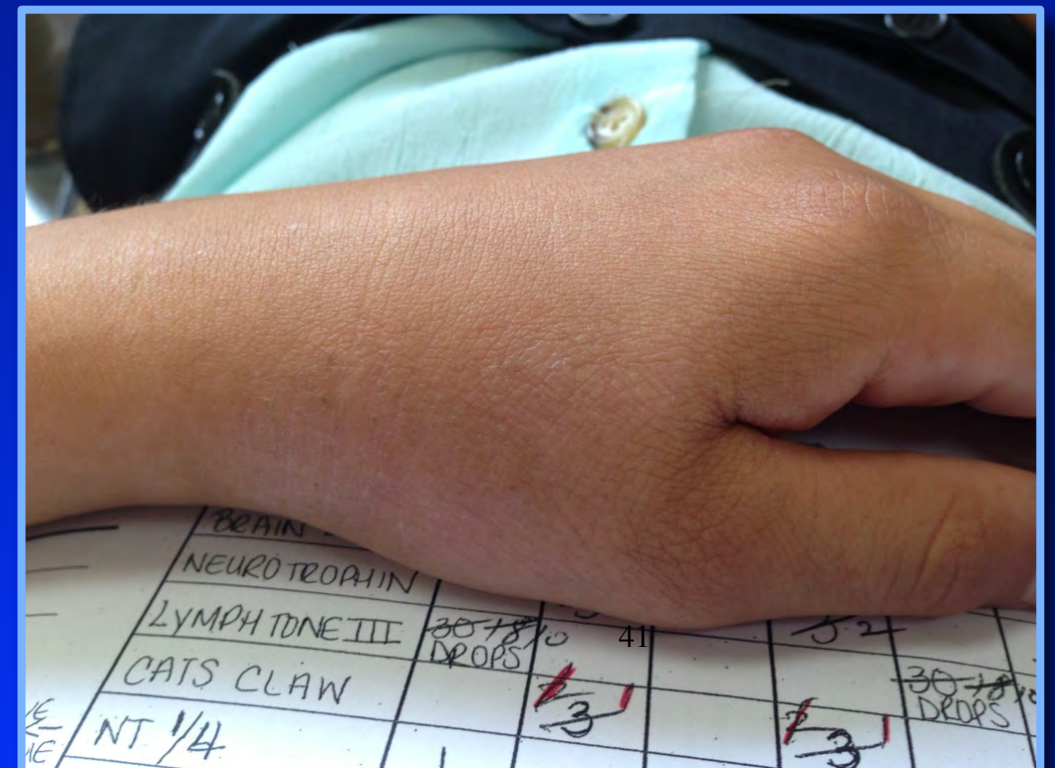HERPES ZOSTER/SIMPLEX/CMV



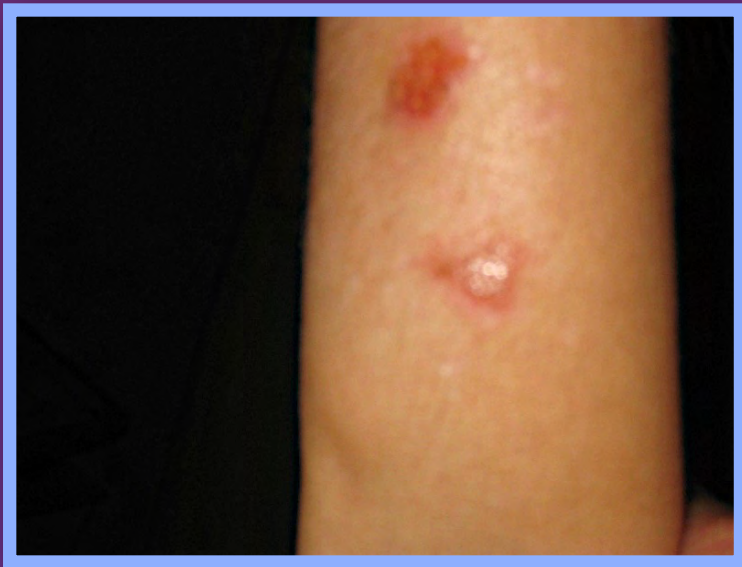3 Months Tx
Nutritional
Support:
vitamins
herbs
homeopathics



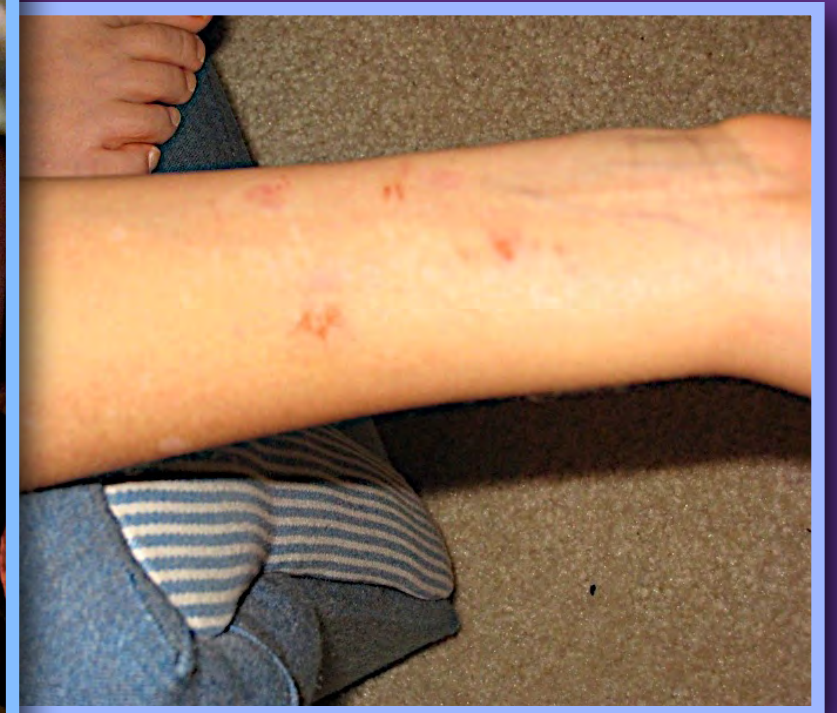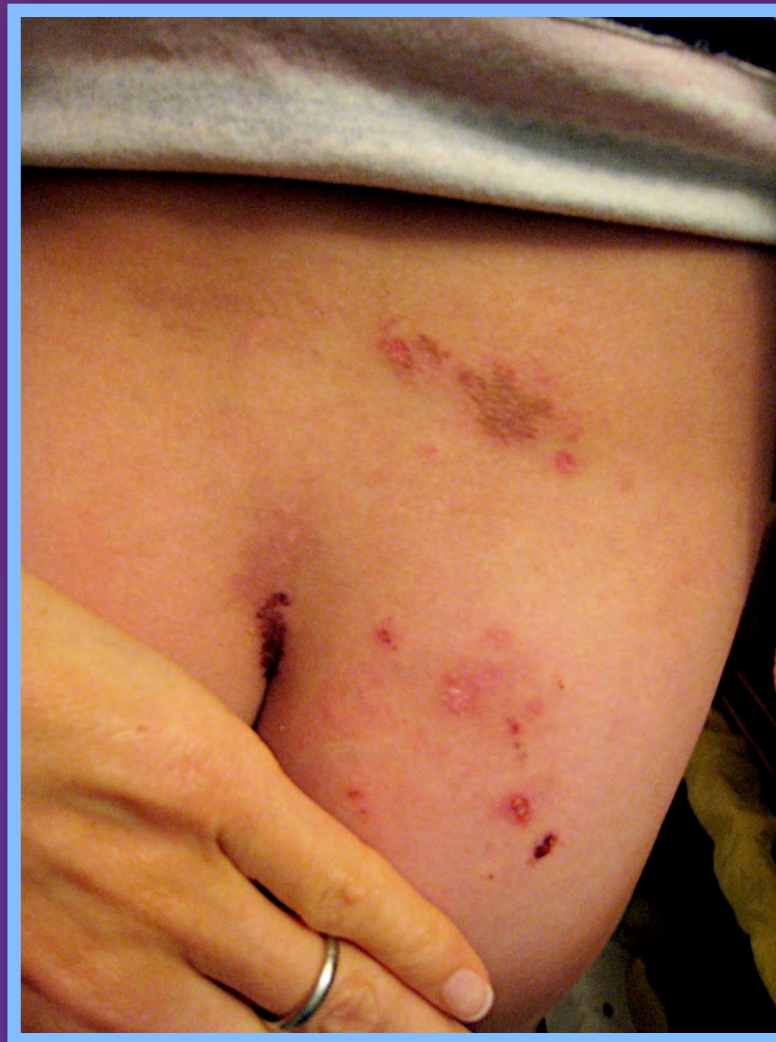Must use
food based
remedies for
maximum
results



A. M.



60 medical
doctors
consulted on
this case



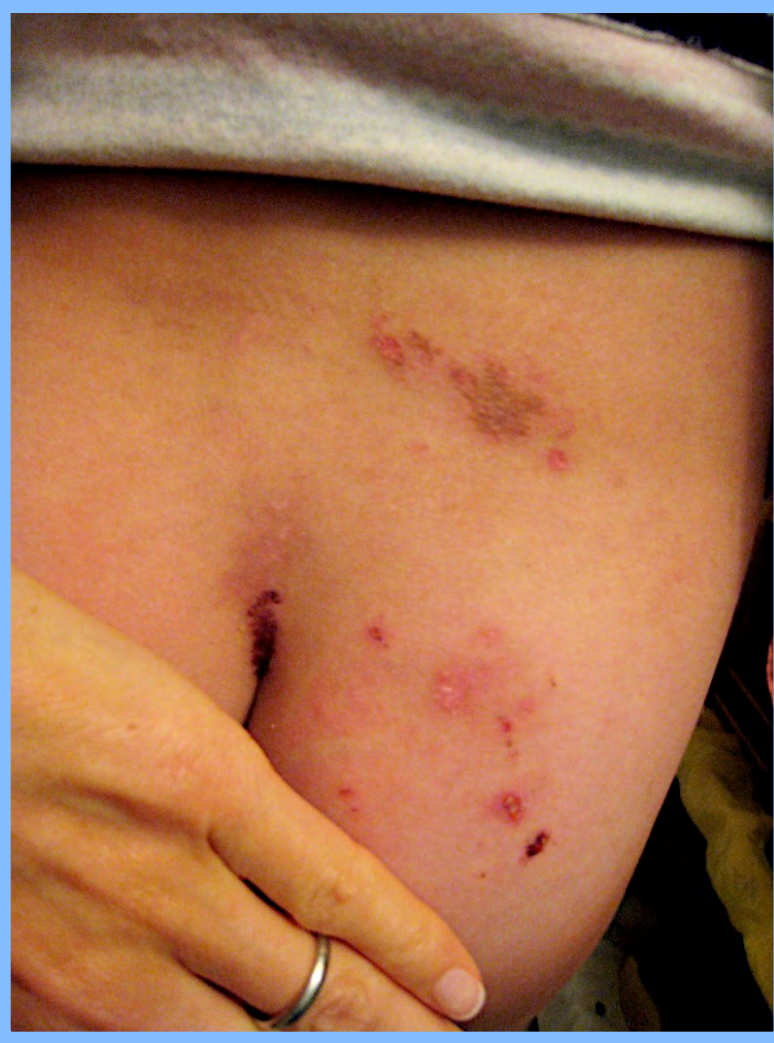Biopsy revealed an
inflammatory
process

**“THE UNIVERSE IS MADE
UP OF ELECTRONS,
PROTONS, NEUTRONS,
AND MORONS”**

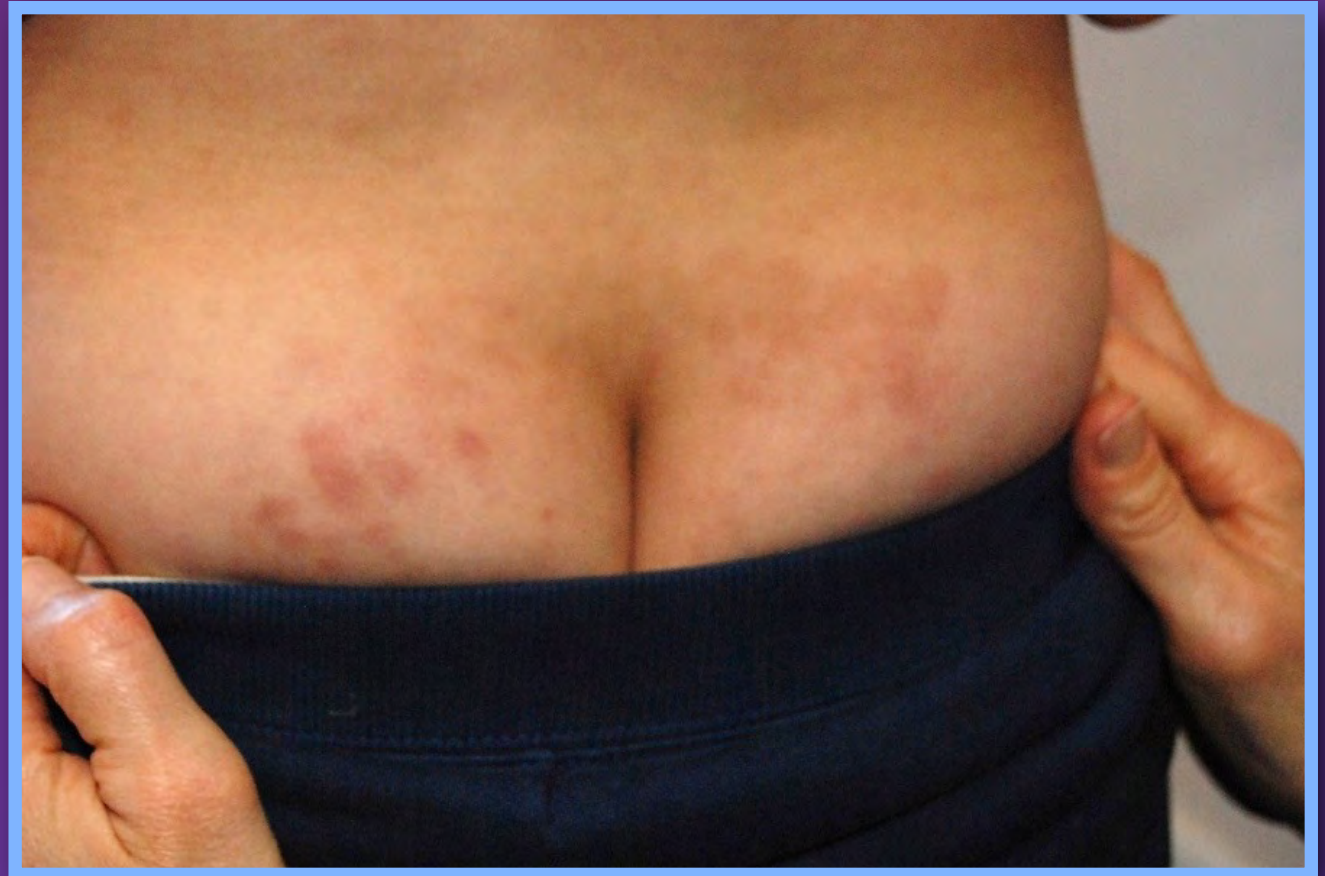

Carl Sagan
ASTROPHYSICIST

A. M.

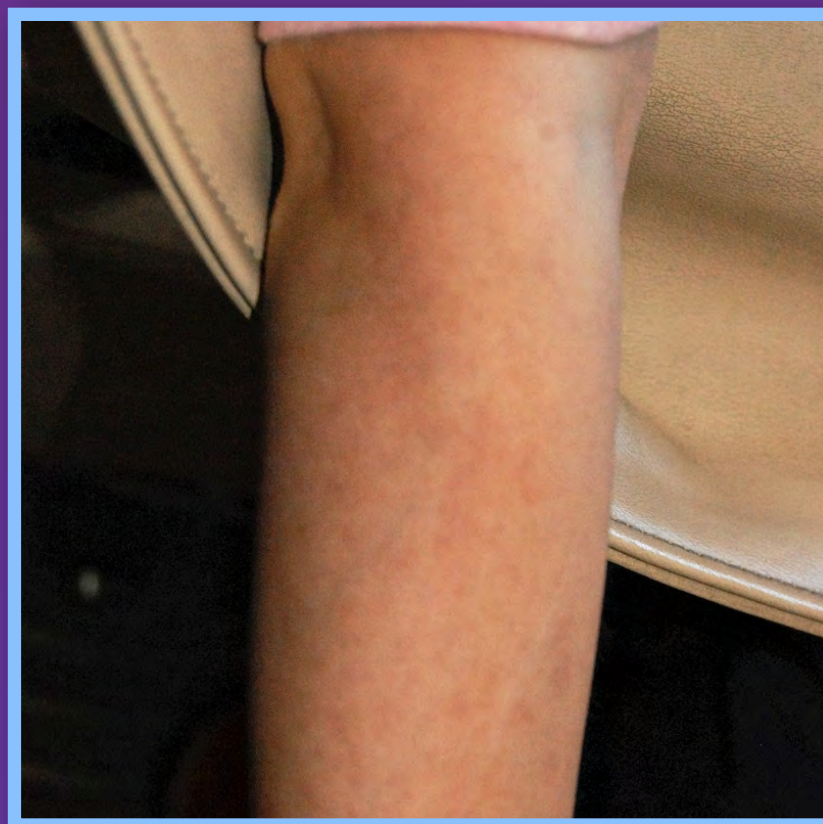
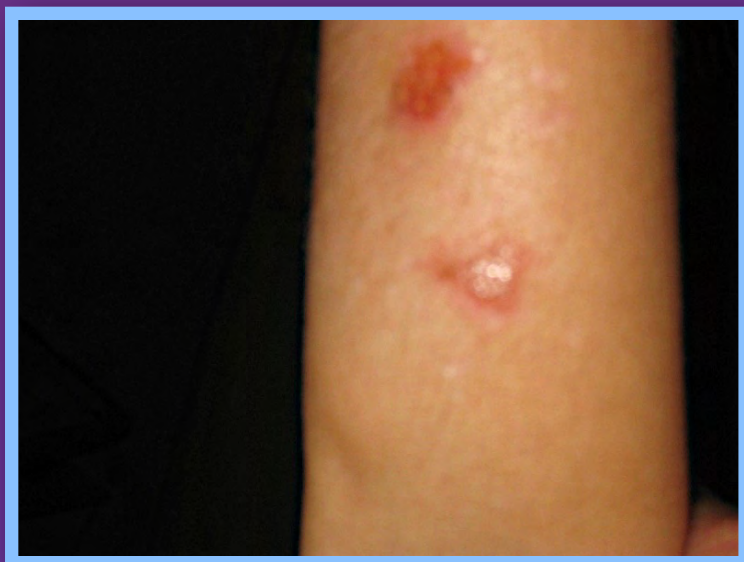
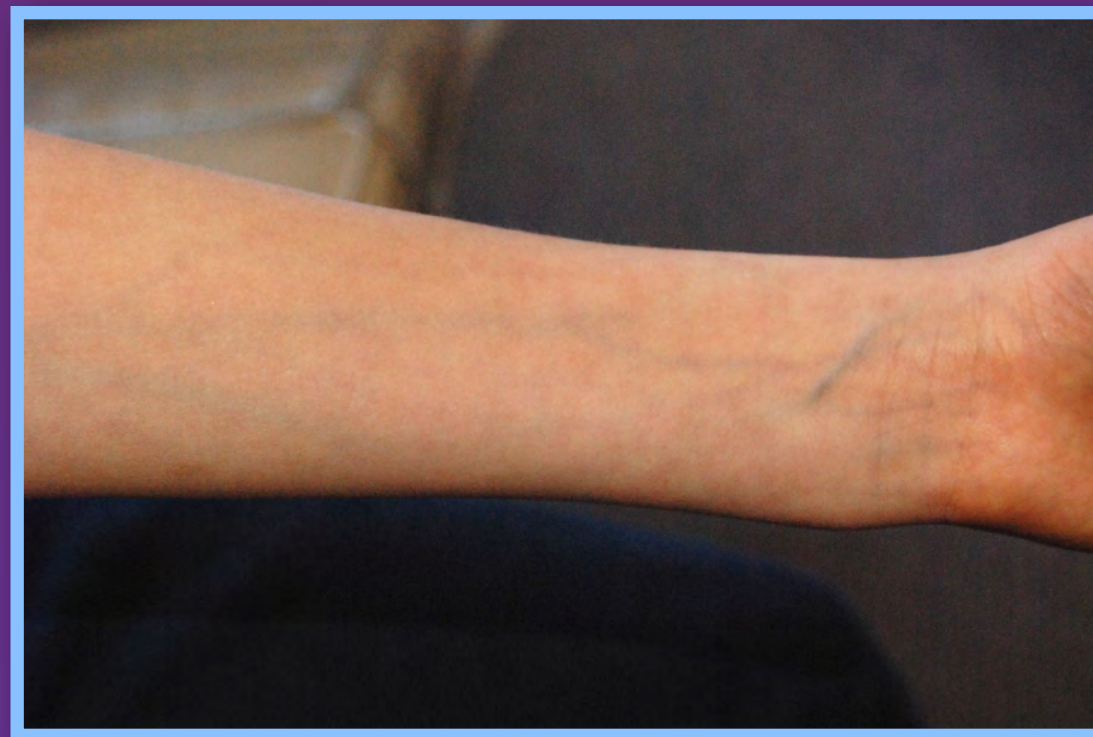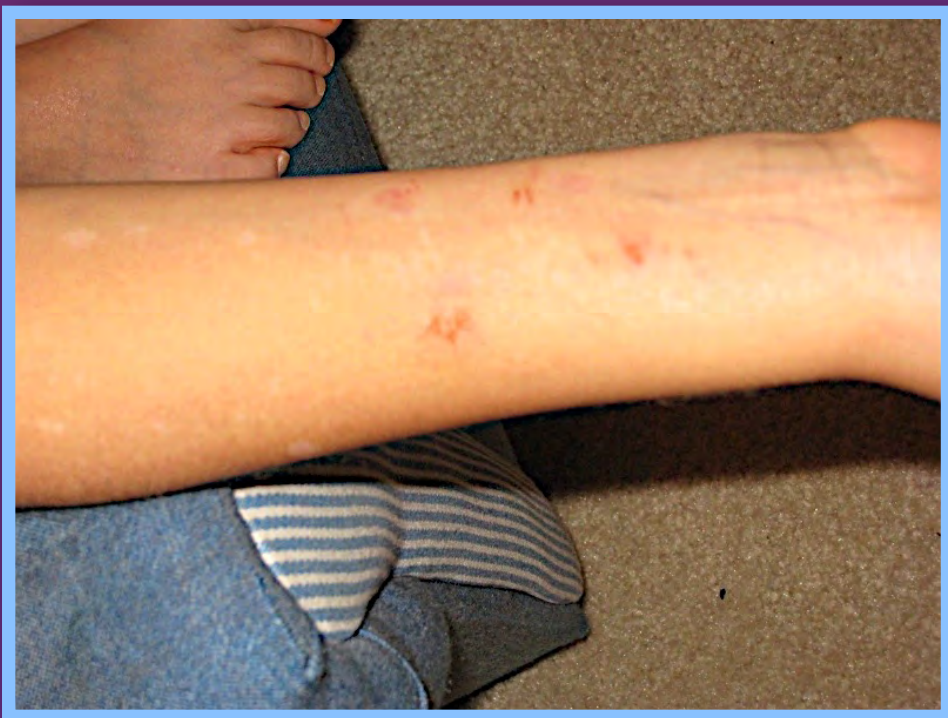- Two rounds of anti-biotics: internal and topical (Dapsone);
- Topical steroids
- Low dose Naltrexone (hepatotoxic)



One month on
Vaccine Chord:
homeopathic
nosode

A. M.



Steroids and
antibiotics drive
infections
deeper into the
cells.

Quantum Testing Approach To Diagnosing

A. M.

Quantum Diagnostic Testing

- Left Lobe of Thyroid - Tetanus vaccine
- Left Tonsil - Diphtheria vaccine
- Lower left small intestine- Candida
- Right leg blisters- Herpes Zoster

Case totally resolved in 7 months

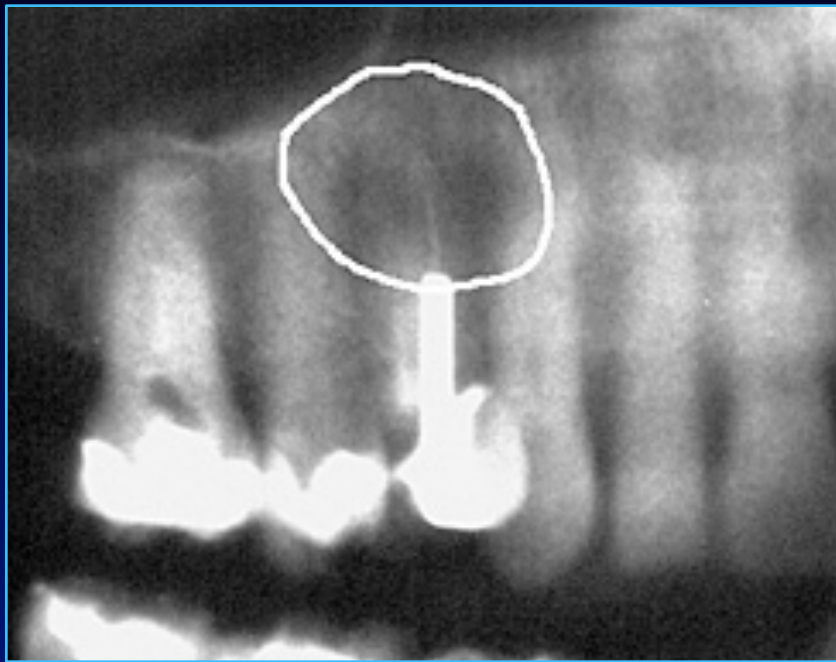
PHYSIOLOGICAL COMPLEX

LIVER TRANSPLANT AVERTED



Nine years ago Fred Schmidt was told he needed a liver transplant. His liver was swollen for 27 years and all of the high tech blood tests and other diagnostics could not diagnosis his problem. In one hour, the Quantum Testing Technique uncovered benzene and hepatitis B in his liver. Natural food based supplements were prescribed and seven months later all his liver enzymes and blood tests were normal.

Dental Dermatological Connection

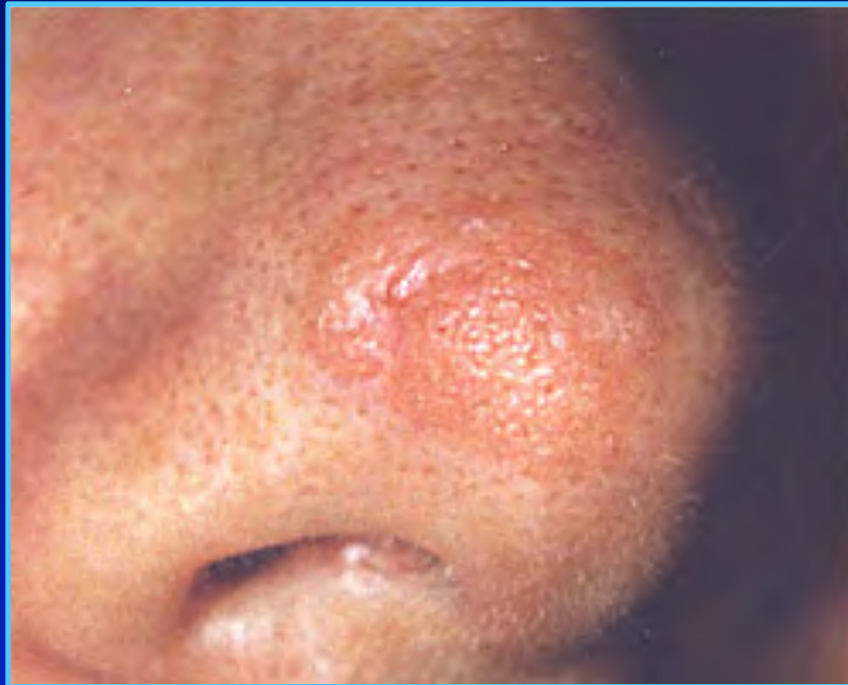

20 year-old root canal

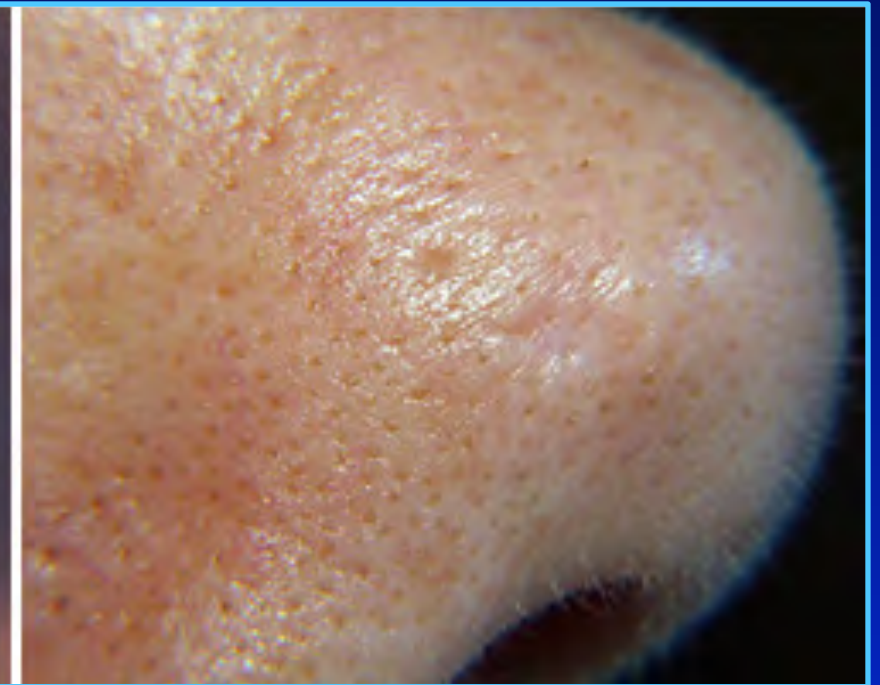Asymptomatic teeth are frequently considered sterile and harmless.

Dx:

Jaw osteitis and streptococcus viridans



Pre-extraction



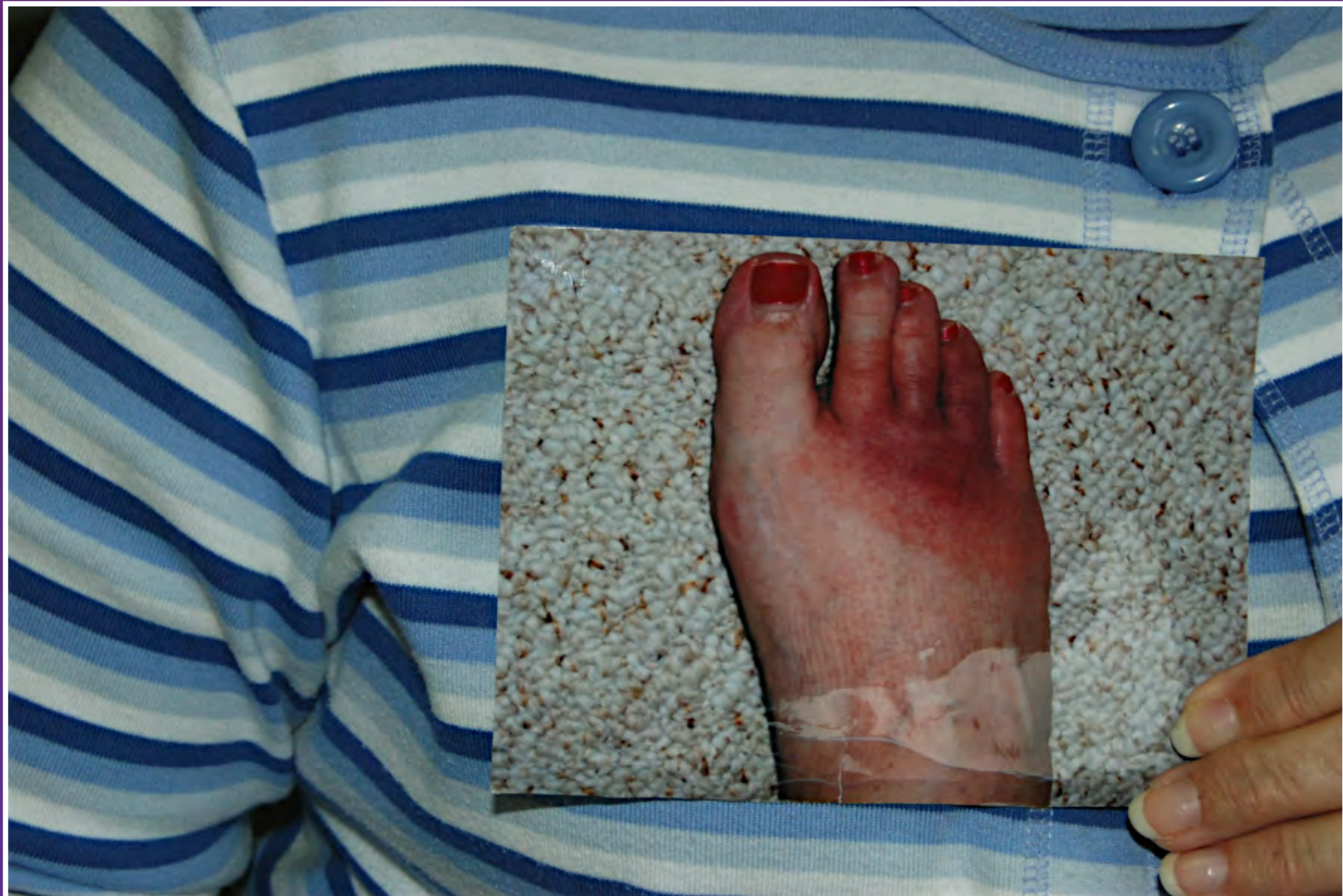Post-extraction

According to Edward C. Rosenow, MD, head bacteriologist of the Mayo Clinic in the 1940's, negative pulpless teeth in his experience were more specifically virulent than those isolated from radiographically positive teeth (teeth with abscesses).

**2.5 year Bell's
Palsy resolved in
2.5 months**

Quantum Testing Approach To Diagnosing

SPIDER BITE



2.5 years ago (2008) patient developed Bell's Palsy soon after a spider bite. No medical diagnosis of the etiology could be made despite numerous tests.



Quantum Testing diagnosed Lyme in the site of the bite and left facial nerve complex. Three months Tx resolved symptoms by 95%.



PSYCHOLOGICAL COMPLEX

BIOPOLAR DISORDER

Reverend H. S. suffered bipolar disorder for 25 years. His father was a dentist and filled his decayed teeth with mercury fillings. Mercury leaks out 24/7 and was in his brain (mania) and his thyroid causing depression. Once his mercury fillings were removed and I put him on a detoxification program, which required 18 months, his bipolar disorder totally disappeared and never returned.

PATIENT HEARING VOICES IN HER HEAD

Dale had her husband bring her to me because she was hearing voices in her head. One of the questions asked during her medical history was do you live or work near a coal burning power plant. The patient responded yes about a mile away from where I work. When evaluated by the Quantum Testing Tech, Dale had high levels of mercury in her thyroid. After ten days of detoxing the mercury out of her thyroid, the voices stopped in her head. Since she quite her job, she never had a recurrence.

Why Medicine and Dentistry's Paradigm is Obsolete

LABORATORY TEST ILLUSION


**A STUDY THAT REVIEWED 2300
AUTOPSY REPORTS**

- ✦ MEDICAL HISTORY ESTABLISHED CORRECT DIAGNOSIS IN 76% OF CASES.**
- ✦ PHYSICAL FINDINGS ACCOUNTED FOR 12% ACCURACY IN MAKING THE CORRECT DIAGNOSIS.**
- ✦ LABORATORY TESTS ACCOUNT FOR ONLY 11% ACCURACY IN MAKING A CORRECT DIAGNOSIS.**

Dental Congestive Heart Failure Connection

Congestive Heart Failure Dental Connection

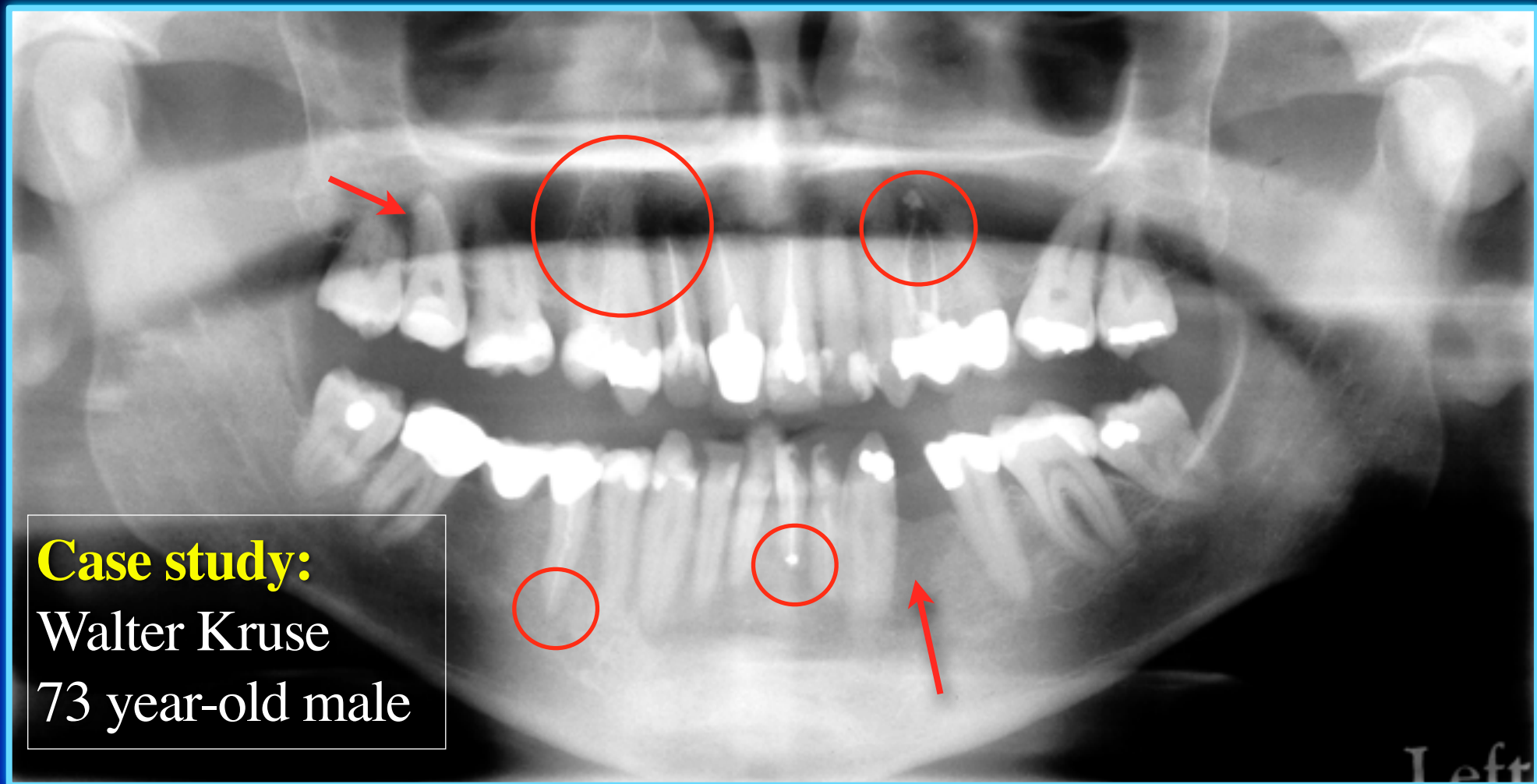
Walter Kruse



Walter walk out of hospice and lived six years with a high quality life. The conventional medical establishment killed Walter when they placed him on Coreg at 4x the normal dose.

Death by Medicine. By Gary Null, PhD; Carolyn Dean MD, ND; Martin Feldman, MD; Debora Rasio, MD; and Dorothy Smith, PhD.

Congestive Heart Failure Dental Connection



- Patient was in hospice suffering with severe congestive heart failure waiting to die.
- University of Pennsylvania told him he needed a heart transplant.

Dx: Hg poisoning, Candida, Cytomegalovirus, Herpes Simplex 2, Staphylococcus, Streptococcus, osteomyelitis

Tx: Biofrequencies and 80 vitamins a day

Results: Patient's severe congestive heart failure was reversed in seven months!

Atypical Facial Pain



C.C. Severe Facial Pain lower right mandibular area near canine.

Dawn McMahon

Medical/Dental History

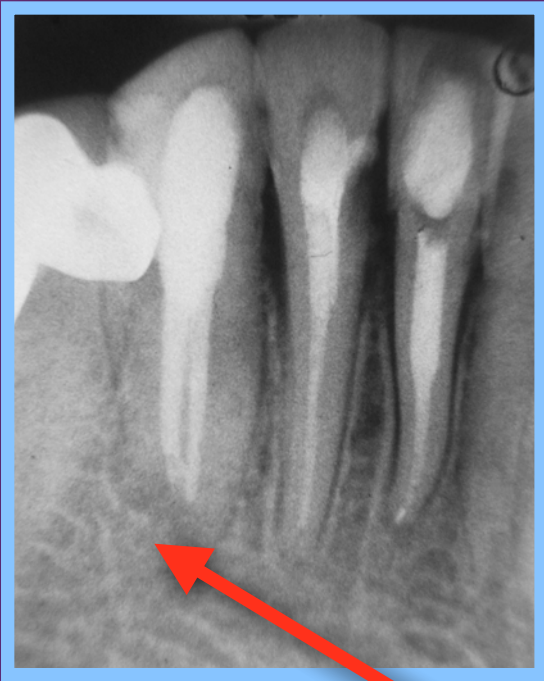

Dawn McMahon

- Nerve Blocks - #27 Failed
12/05 thru 3/06
- Root canal on #27- failed
- Root canal re-treatment- failed
- Apico- failed
- Ablation of mental nerve- Failed
- 4/06 Gamma knife- failed
- 9/06 Craniotomy (32 staples)- failed

Common Dental Issues

Dawn McMahon

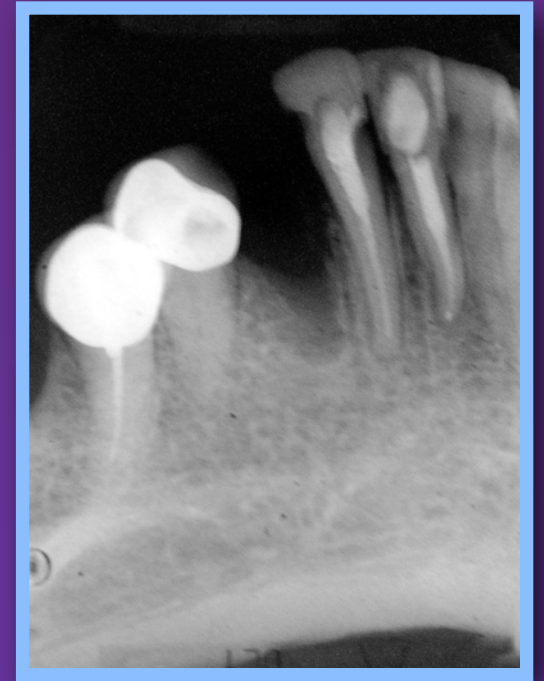

Medical/Dental History

C.C. Severe Facial Pain lower right mandibular area near canine.


Direct Resonance Testing:

- Herpes Zoster
- Herpes Simplex I



“Modern” Dental Technology is based on Neanderthal Mentality.

Chronic Spiking Blood Pressure



John K. had chronic blood pressure issues for over 15 years. All traditional medical treatment plus alternative methods did not control John's spiking BP.

Quantum Testing diagnosed intestinal parasites. A 90 day food grade diatomaceous earth protocol (1 tablespoon mixed in 12 ounces of water taken first thing upon arising). Following the 90 day cycle his BP spiking totally resolved.

KISS Principle

Keep It Simplistically Simple

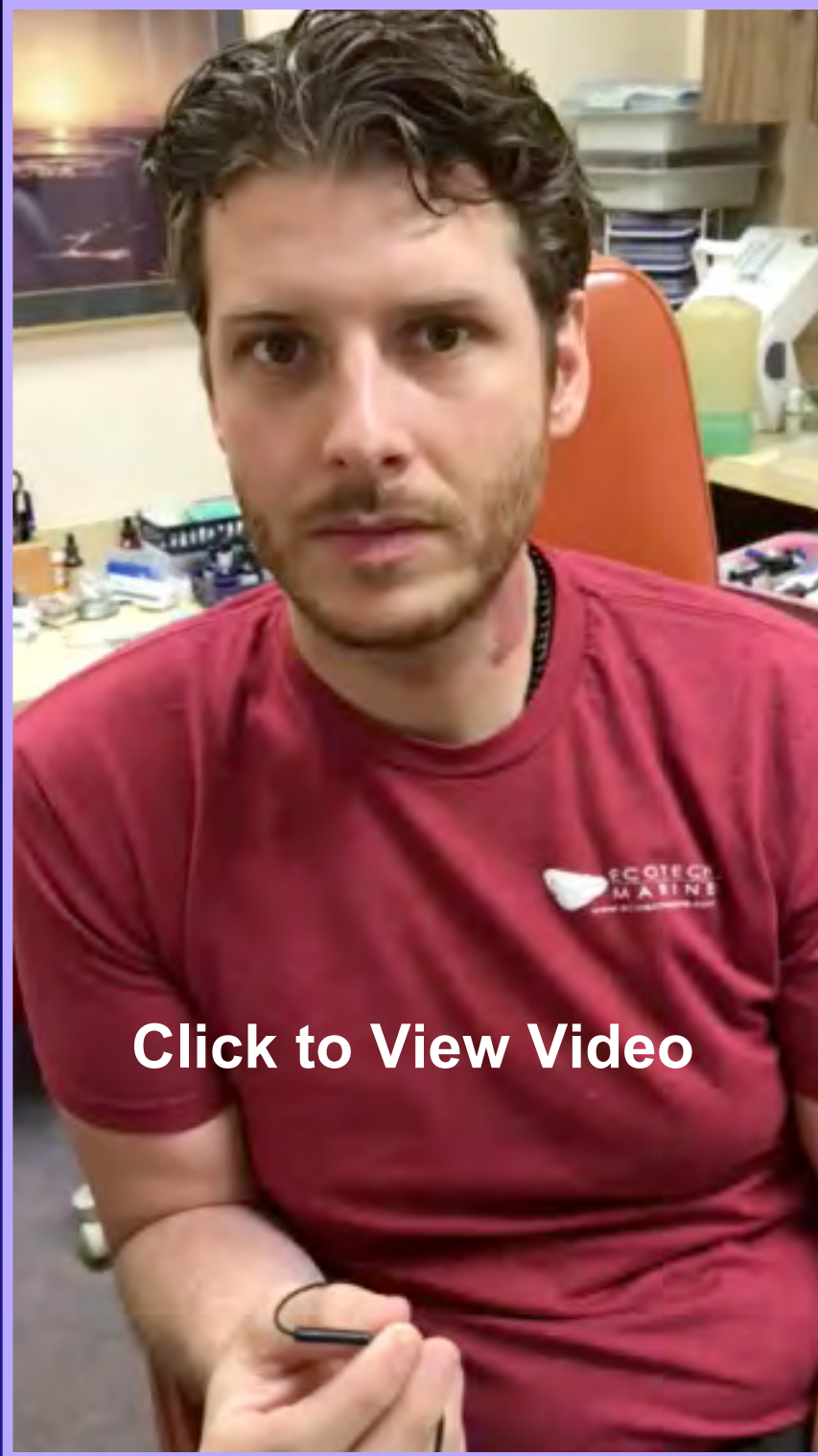
Vertigo totally Resolved With a Custom Homeopathic Remedy



In 2017, ninety year old Carmen Mazzuca was given Ciprodex to treat a left ear infection. Within 10 minutes after taking the medication he developed severe vertigo. For over 1 year Carmen sought medical help with no results.

Tx: Quantum testing Dx that the Ciprodex was trapped within the nerves of his left ear. A 30C potency of the drug was custom made. From the first oral dose of 9 drops Carmen's vertigo disappeared totally.

Chronic Shingles



In September 2017 Patrick Clasen was diagnosed with herpes zoster. Over the following year he endured seven major bouts of shingles outbreaks, which caused severe muscle spasms and burning pain in his neck and upper back. Traditional medicine prescribed Valacyclovir, which unfortunately did not resolve his problem.


Chronic Shingles

Patrick was shown to have an underactive thyroid. His thyroid gland was contaminated with elementary mercury, cytomegalovirus (CMV), glyphosate (Monsanto's Roundup), and tetanus vaccine. Patrick's upper left central incisor was contaminated with cytomegalovirus, which was also present in his jawbone where his lower left wisdom tooth was extracted. These two areas served as toxic waste dumps from which the lymphatic system of the mouth drained its toxic wastes into the thyroid gland. It is very interesting that none of his physicians ever picked up on these critical issues.

Patrick was placed on a nutritional program, plus biofrequencies to destroy the herpes zoster virus (Shingles) as well as the CMV. The results were no less than spectacular. Patrick's pain totally resolved.

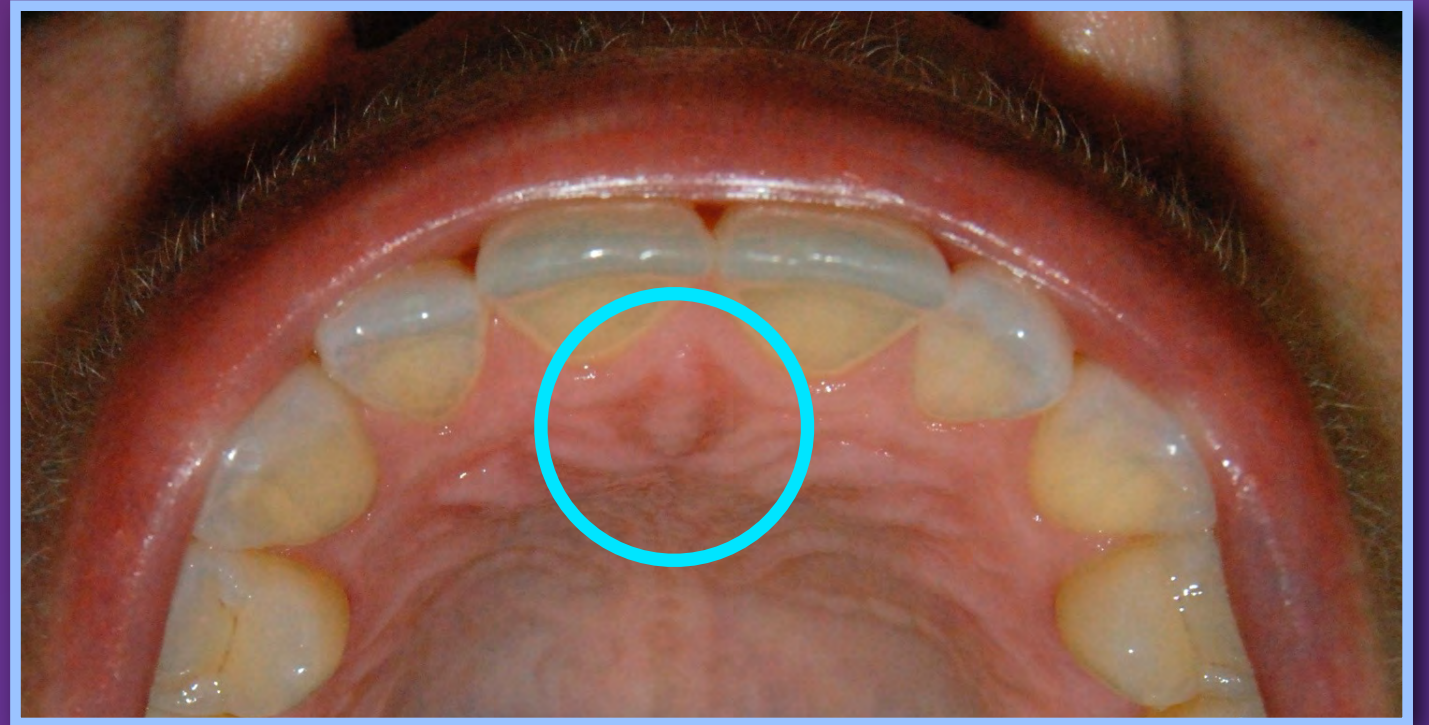
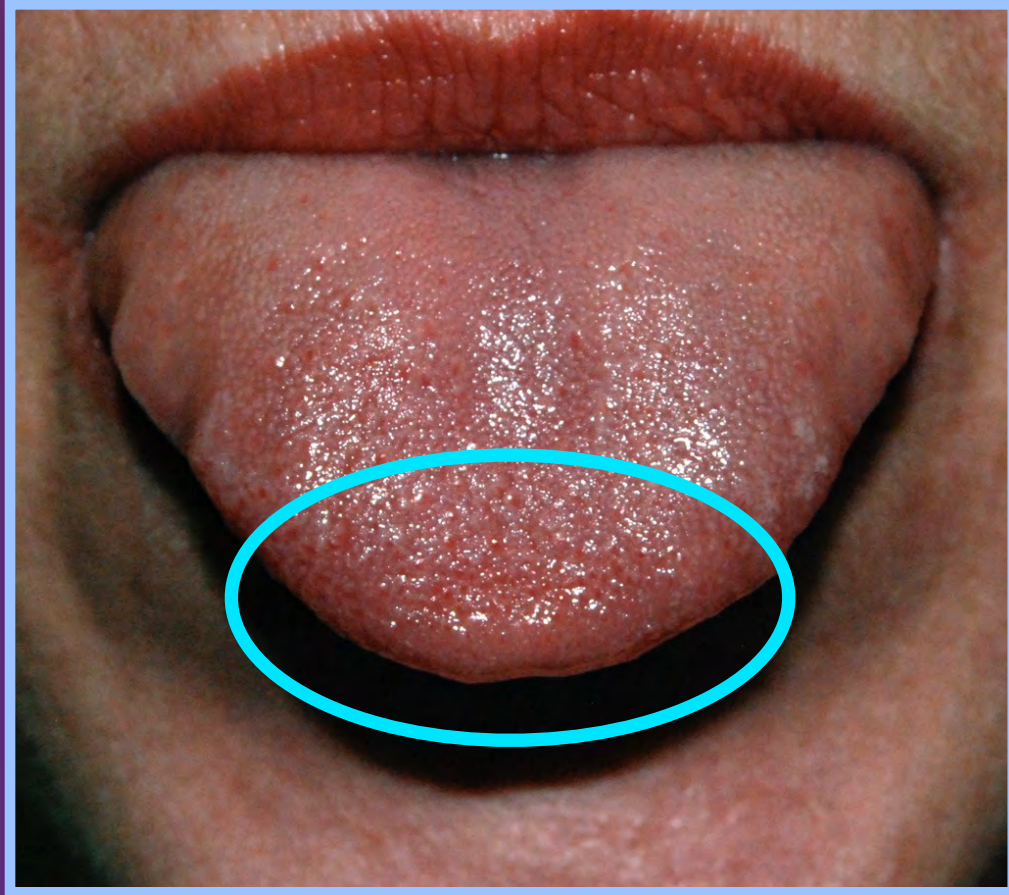Uncommon Dental Issues

Ten Years of Sever Oral Pain



Oral Herpes Zoster

Severe Oral Pain



Quantum testing made the diagnosis of shingles in both areas. Homeopathic HZ (Energetix), nutrients (Alli-C, SOD, DHLA, calcium, flax oil, and Rife Generator were used to resolve the virus.

Cardiac Sarcoidosis

Mayo Clinic's website states that there is **NO Cure**.
Their Tx ranged from steroids all the way to
a heart transplant.

Define the “Splinter”

The medical history is accurate 76% in making a correct diagnosis

Click to View Video



During his medical history, Data mentioned that while growing up in India he was exposed to DDT as a child when he and his friends would chase the truck spraying it.

Define the “Splinters”

Quantum Testing Technique found:

- Hypothyroidism
Thyroid gland had: DDT, glyphosate (Monsanto's Round-up), tetanus vaccine, formaldehyde, aluminum, mercury, and Lyme
- **Prostate gland:** DDT, glyphosate, formaldehyde, aluminum, mercury, and Lyme
- **Heart:** DDT, glyphosate, tetanus vaccine, formaldehyde, Streptococcus viridans aluminum, mercury, flukes, and Lyme
- **Mandibular left root canal:** Streptococcus viridans
- **Facial vitiligo:** DDT and formaldehyde
- **Liver:** mercury, flukes, toxoplasmosis
- **Small intestines:** parasites (flukes)

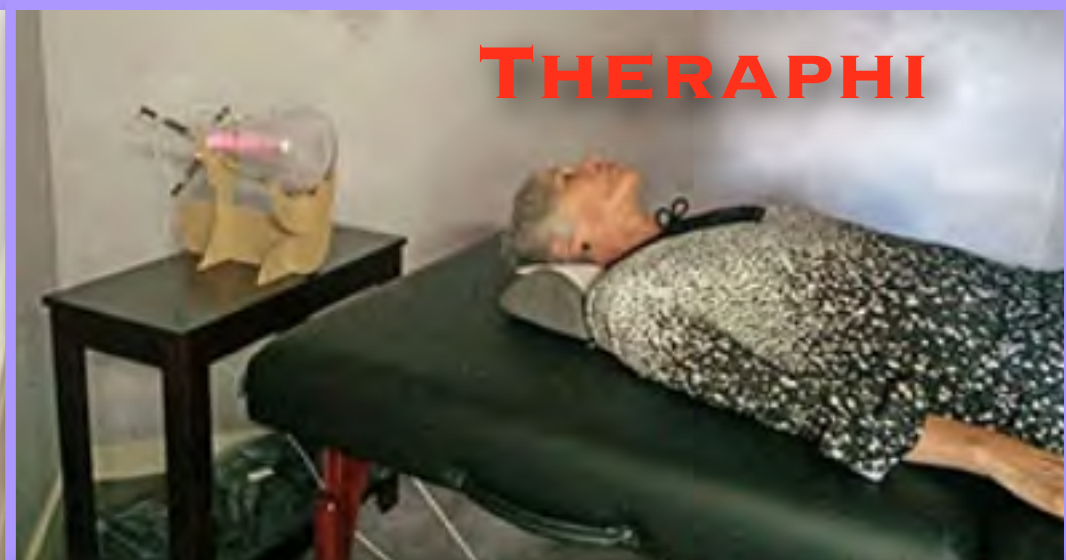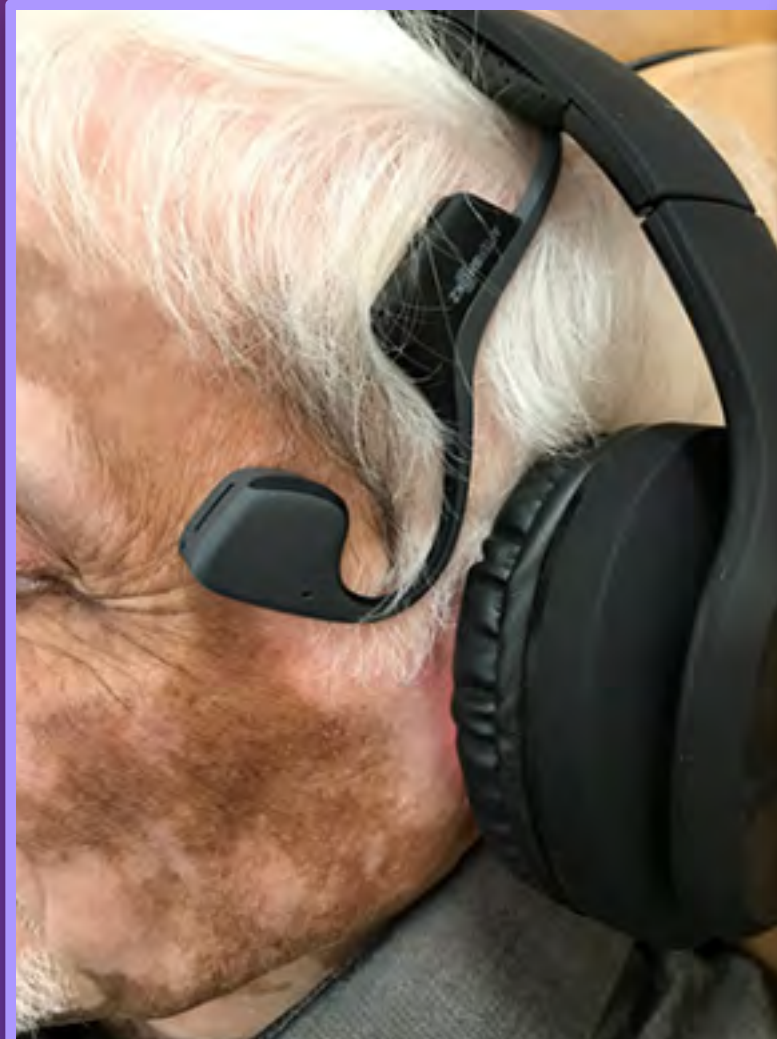Define the “Splinters”

Remove the “splinters” and Watch the Body Heal

The patient was placed on an extensive regime of food based supplements to resolve the specific initiators. Every supplement prescribed was energetically tested for compatibility with the patient's energy pattern. Scalar energy (Theraphi) and cutting edge infrared technology coupled with bone conducting vibratory sound frequencies to heal the brain and rest of the body.

Energetic Healing

Cutting edge infrared technology coupled with vibratory sound frequencies to heal the brain and rest of the body.



Define the “Splinters”

Five months post-Tx

The patient returned on November 5, 2019 for follow-up treatment and reported the absence of shortness of breath, cough that won't go away, enlarged lymph glands, and fever, weight loss, fatigue, night sweats, general feeling of ill health. Of interest was the fact that all his previous abnormal blood values were now normal.

"Most of the things worth doing in the world had been declared IMPOSSIBLE before they were done." — Louis D. Brandeis

Medical Myth About "Autoimmune Disease"

Hashimoto's Disease

Dental Connection

Lisa Simonetti

22-year-old account
diagnosed with Hashimoto's
disease.

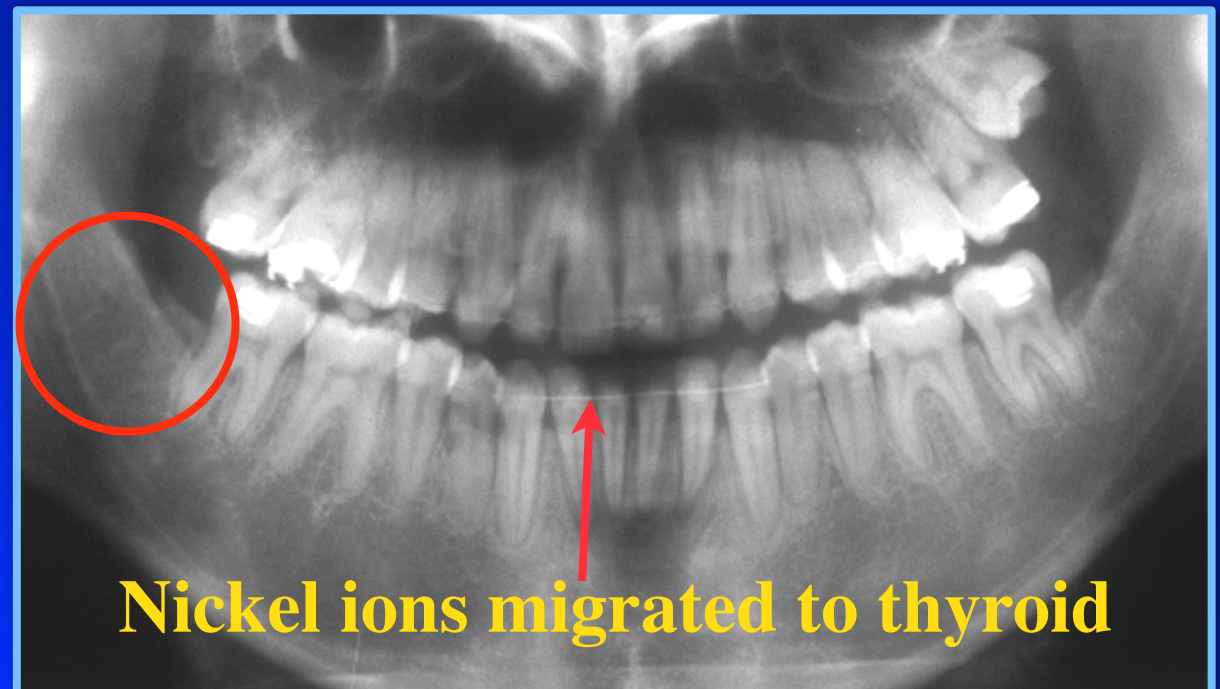
C.C. Severe fatigue, weight
gain, poor memory, insomnia

Medical Tx: Thyroid
hormone. No change

Direct Resonance testing:
CMV and nickel toxicity in
thyroid.

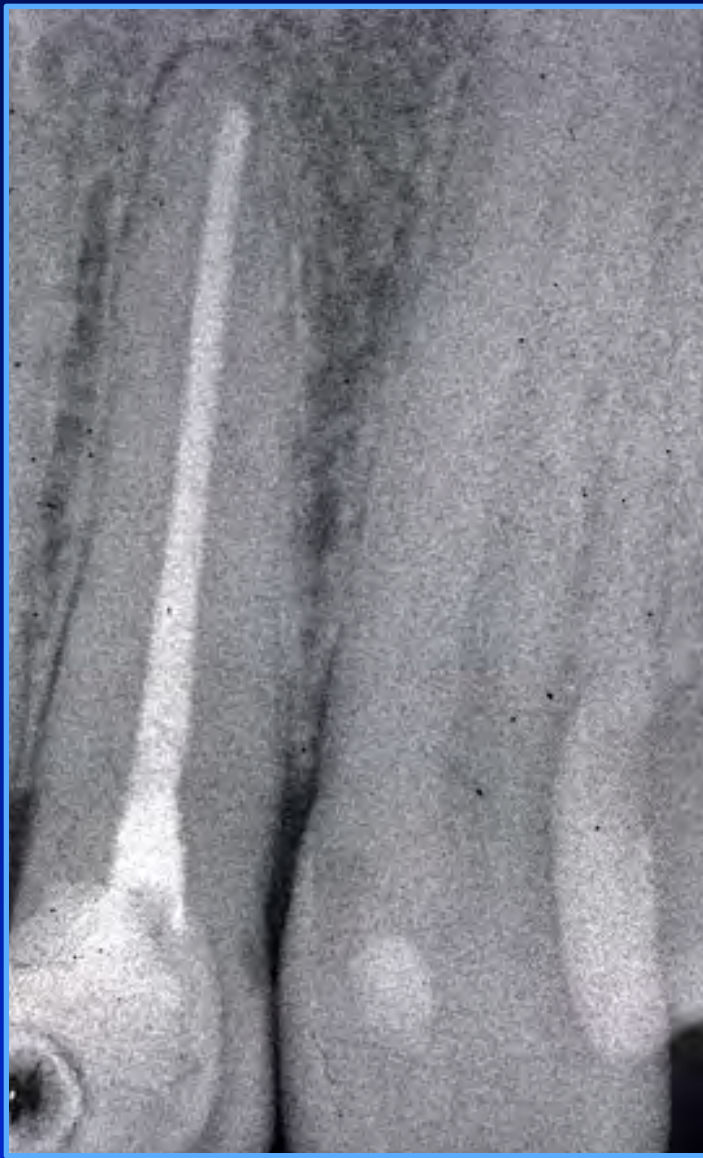1997 - Extraction of lower right third
molar resulted in an infection. CMV
migrated to thyroid.

Hashimoto's disease is classified as an auto-immune problem where the body attacks the thyroid. The primary symptoms are the same as an under active thyroid: tiredness, forgetfulness, depression, coarse dry skin, slow heartbeat, weight gain, insomnia constipation and intolerance to cold. According to traditional medicine there is no cure.



Dental Rheumatoid Arthritis Connection

1973



Root Canal at age 29

- Age 30 - First signs of rheumatoid arthritis: swollen knees appeared one year after root canal therapy performed in tooth #10.
- 1974-2004 -Patient placed on prednisone, methotrexate and Enbrel (yearly cost \$13,500) Enbrel is primarily used to block the tumor necrosis factor alpha (TNF alpha), which the body produces during the inflammatory response.
- 2004 - Quantum Testing : Dx Streptococcus viridans in root canal tooth. Three Txs with biofrequencies eliminated use of Enbrel and reduced swelling and pain by 98 percent.

Dental Raynaud's Disease Connection

Raynaud's Syndrome Dental Connection



Marjan is a dentist who suffered Raynaud's Syndrome for 43 years. She had to place her hands in hot water several times a day just to get the feeling back to continue doing her dentistry.

Dx: Strep viridans infection in maxillary left first bicuspid root canal tooth and mercury toxicity in her thyroid.

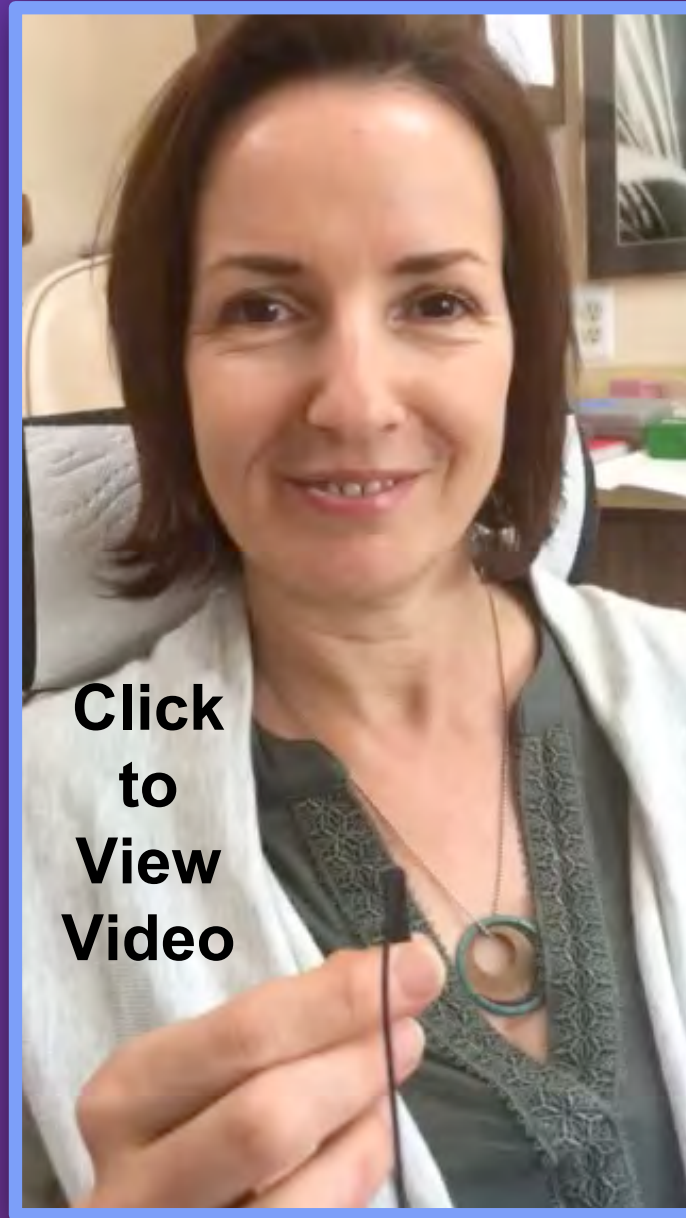Tx: Bio-frequencies to destroy the strep and nutritional supplements to chelate out the Hg from the thyroid. In two weeks the patient had no more symptoms of Raynaud's Syndrome.

Beaming Infrared Laser through A Homeopathic Remedy

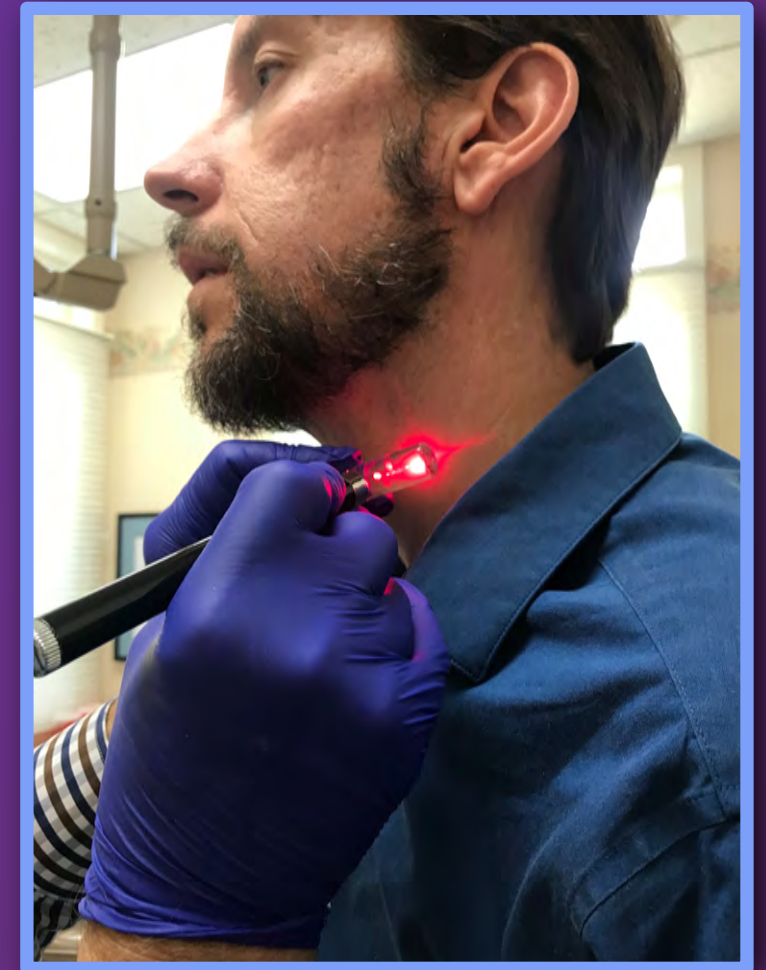Virtual Injection



Test patient for
best frequency:
green (532 nm) or
infrared (650 - 880 nm)



Pain caused by
Glyphosate in liver



Test remedy then pulse
into the area where the
toxin or pathogen exists

Alzheimer's Diseases



*Quantum Testing Diagnosed:
Mercury, Glyphosate and Lyme infection in
the left side of Patrick's brain*

Why Medicine's Approach to Cancer Treatment is Obsolete

CANCER is not a Disease!

**It is a breakdown of the immune
system and an
oxygen deficiency problem.**

Typical Biopsy Report A.W.

Microscopic Description:

Invasive Carcinoma

- Histologic type: infiltrating ductal carcinoma
- Histologic grade:
Overall grade 2
Mitotic score: 1
Architectural score: 3

Breast prognostic marker results

Estrogen receptor: moderate to strong positive, >90%

Progesterone receptor: moderate to strongly positive, > 80%

Interpretation:

Estrogen receptor: positive

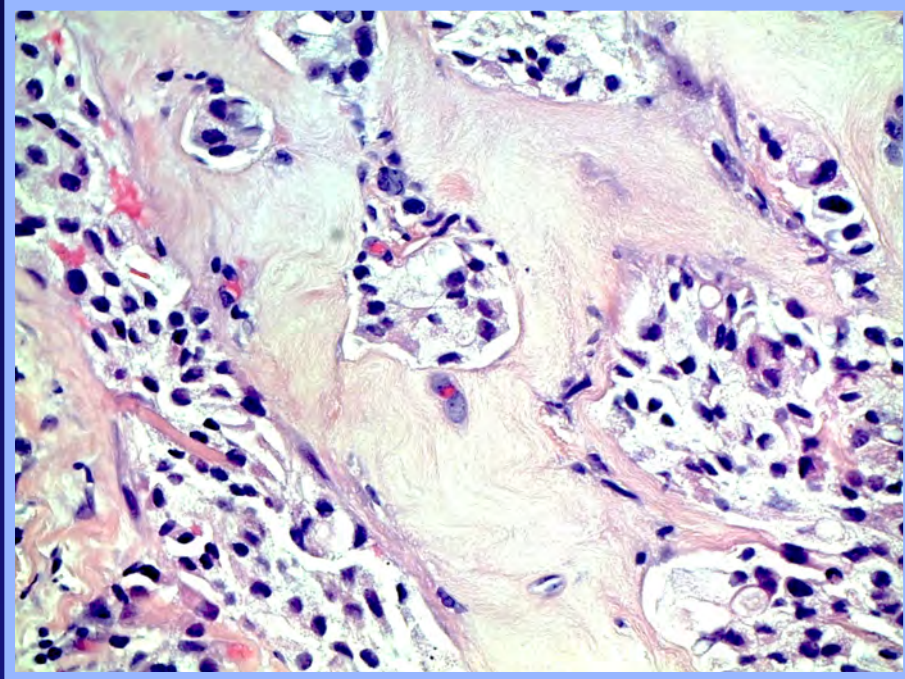
Progesterone receptor: positive

Final Diagnosis: Infiltrating ductal carcinoma, grade 2

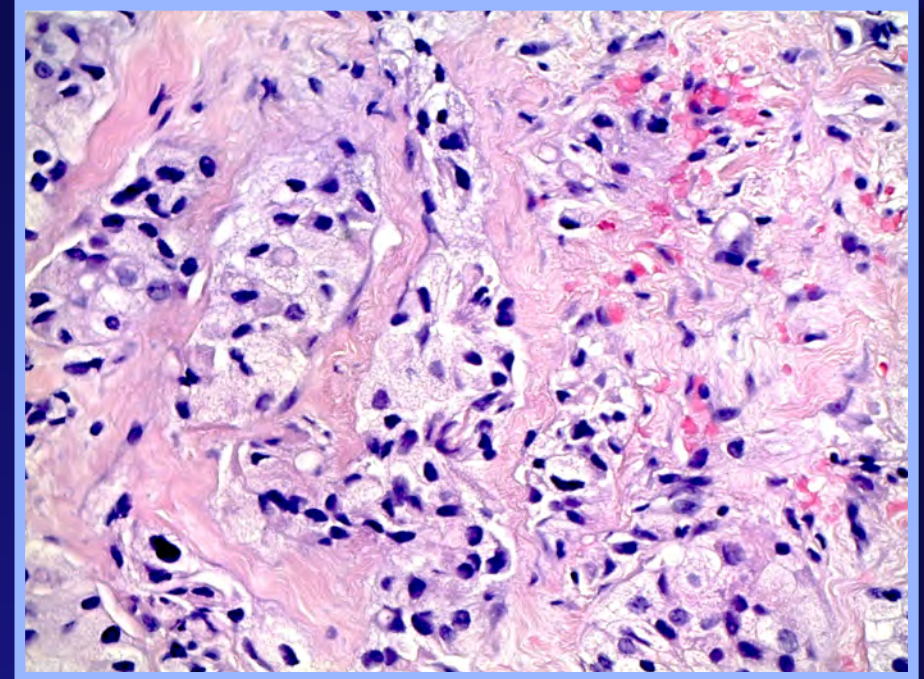
Infiltrating tumor measures up to 7mm in biopsy specimen

No definite angiolymphatic invasion identified

Quantum Testing Findings: A.W.

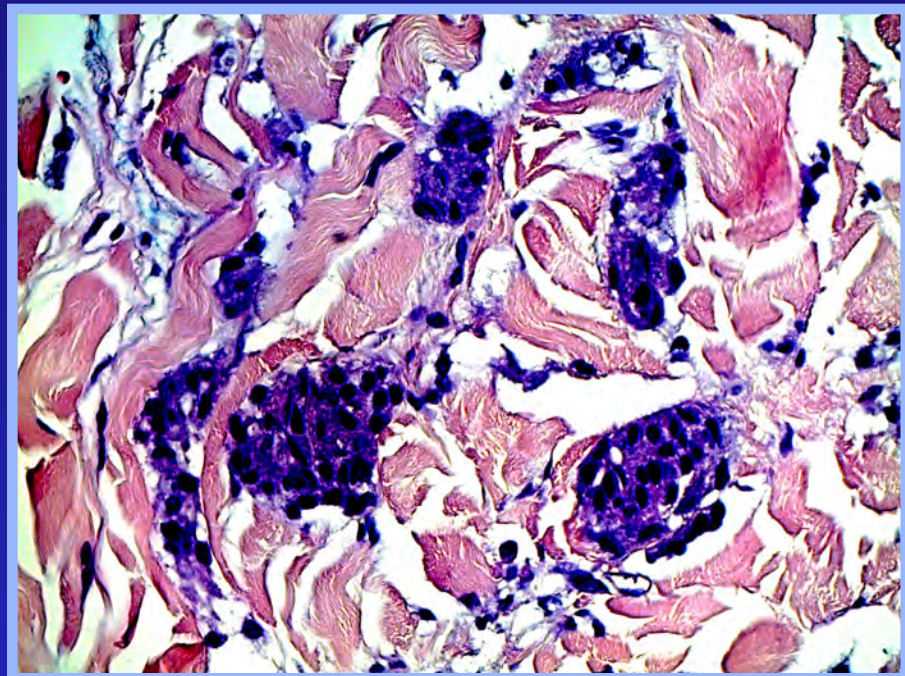


CMV

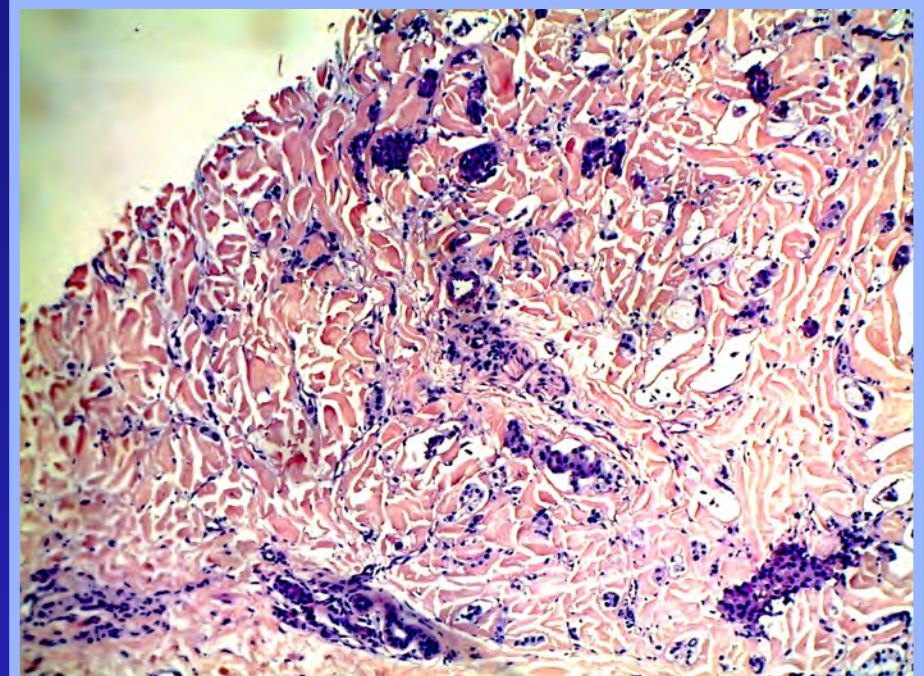


Hep B

Glyphosate



Nickel



12 Steps to Reversing Cancer

To be discussed in next weeks webinar - May 13

Quantum Testing Technique

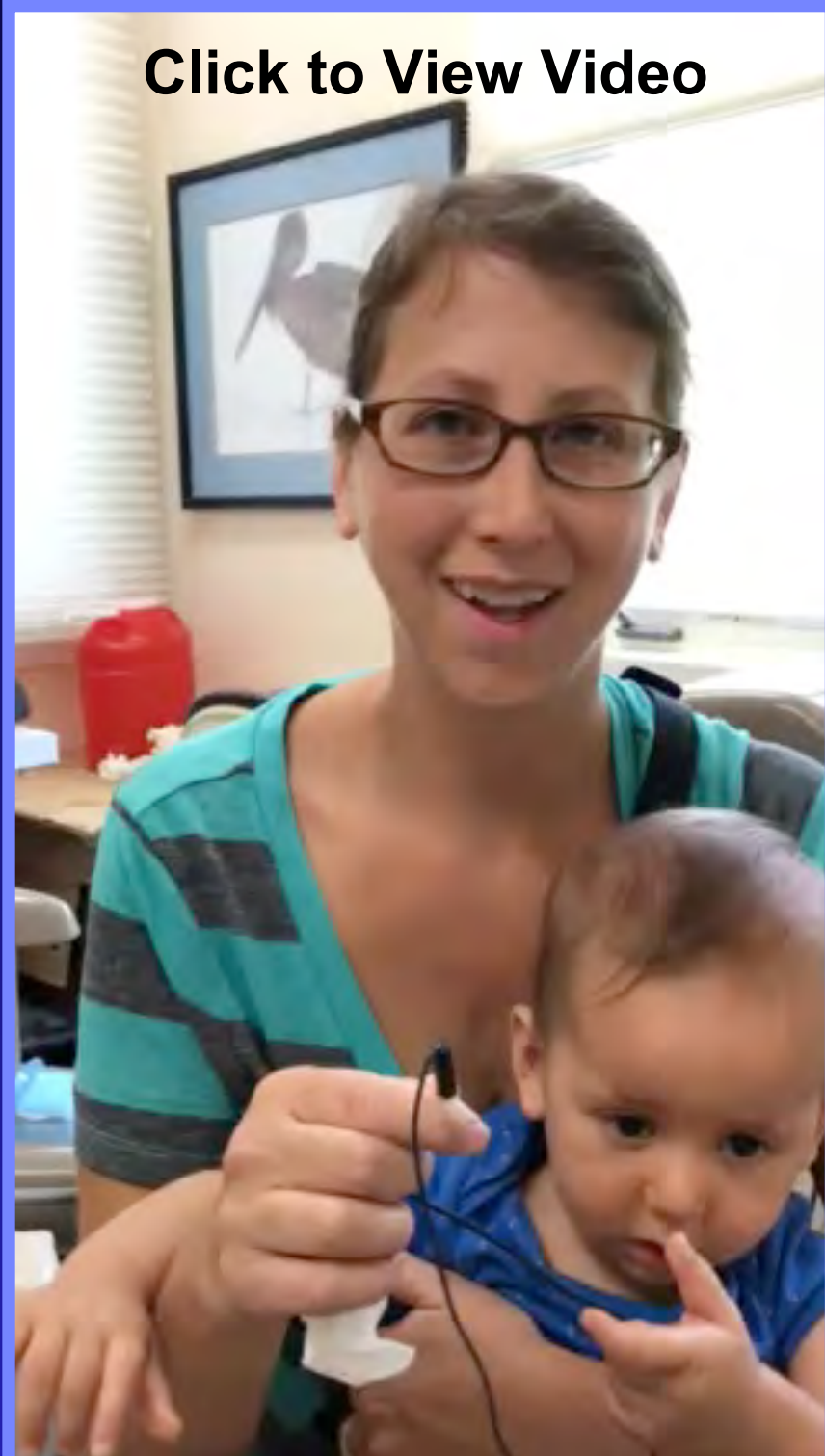Defining the “Splinter(s)”

Infantile Brain Spasms

Vaccine Induced Seizures

Vaccine Induced Seizures

Click to View Video



CHOP had baby Levi on steroids for seizures.

Dx

Viral meningococcal infection in the left side of the brain along with thimerosal (ethyl mercury), glyphosate (pesticide Round-Up) cadmium, aluminum, and lead. A nutritional program was prescribed and tested for compatibility. Within six weeks the child's seizures resolved and he became the loving interactive child he was suppose to be.

Canine Seizures



Winchester, a 3.5 year-old Beagle, suffered from frequent seizures. All conventional veterinary testing failed to define the underlying cause. Using Quantum testing techniques, a diagnosis of mercury in his brain was made. Winchester was placed on a homeopathic remedy, Metal-Chord, to remove the mercury. In six weeks Winchester was totally seizure free.

Lip Cancer

Quantum testing Dx:

- Mercury
- Glyphosate
- CMV
- Parvovirus

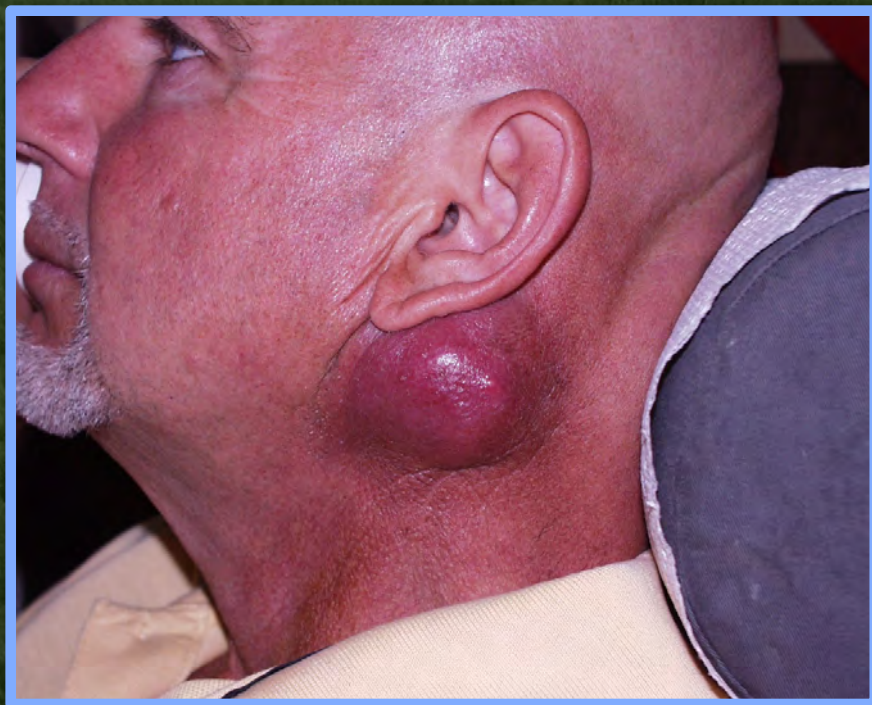

Rosco
Labradoodle

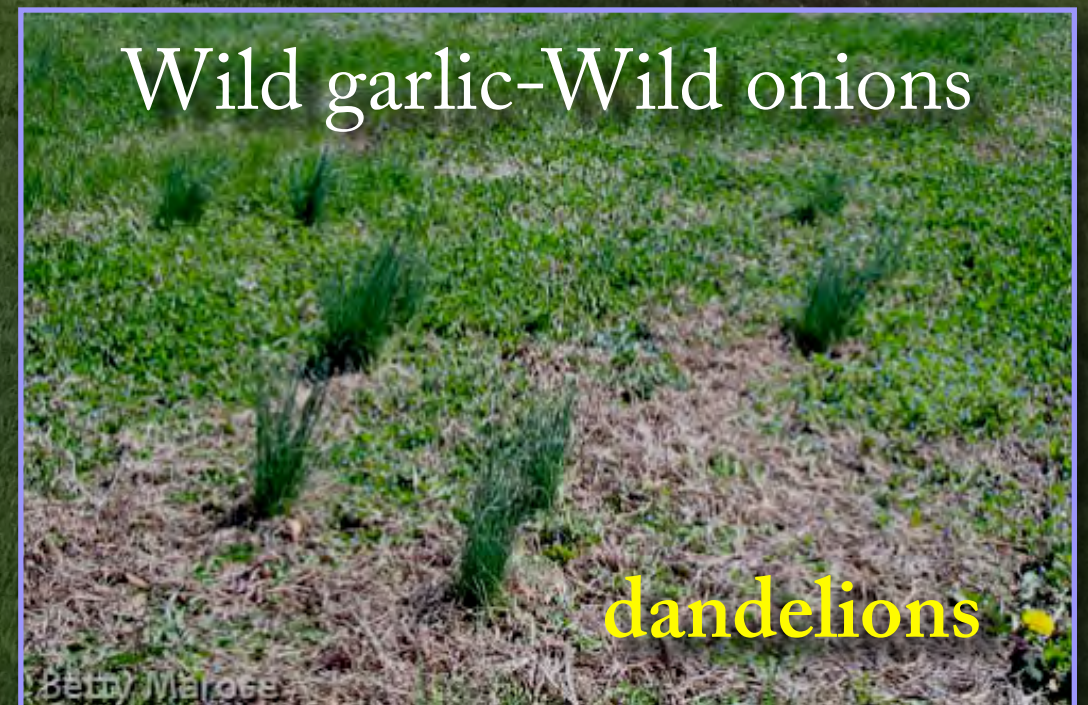Nutritional Tx:

Six weeks after starting the supplement program, Rosco's lip cancer fell off.

ROSCO HAD LIP CANCER; IT WAS CUT OFF TWICE BY CORNELL VETERINARIAN SCHOOL AND IT GREW BACK TWICE.

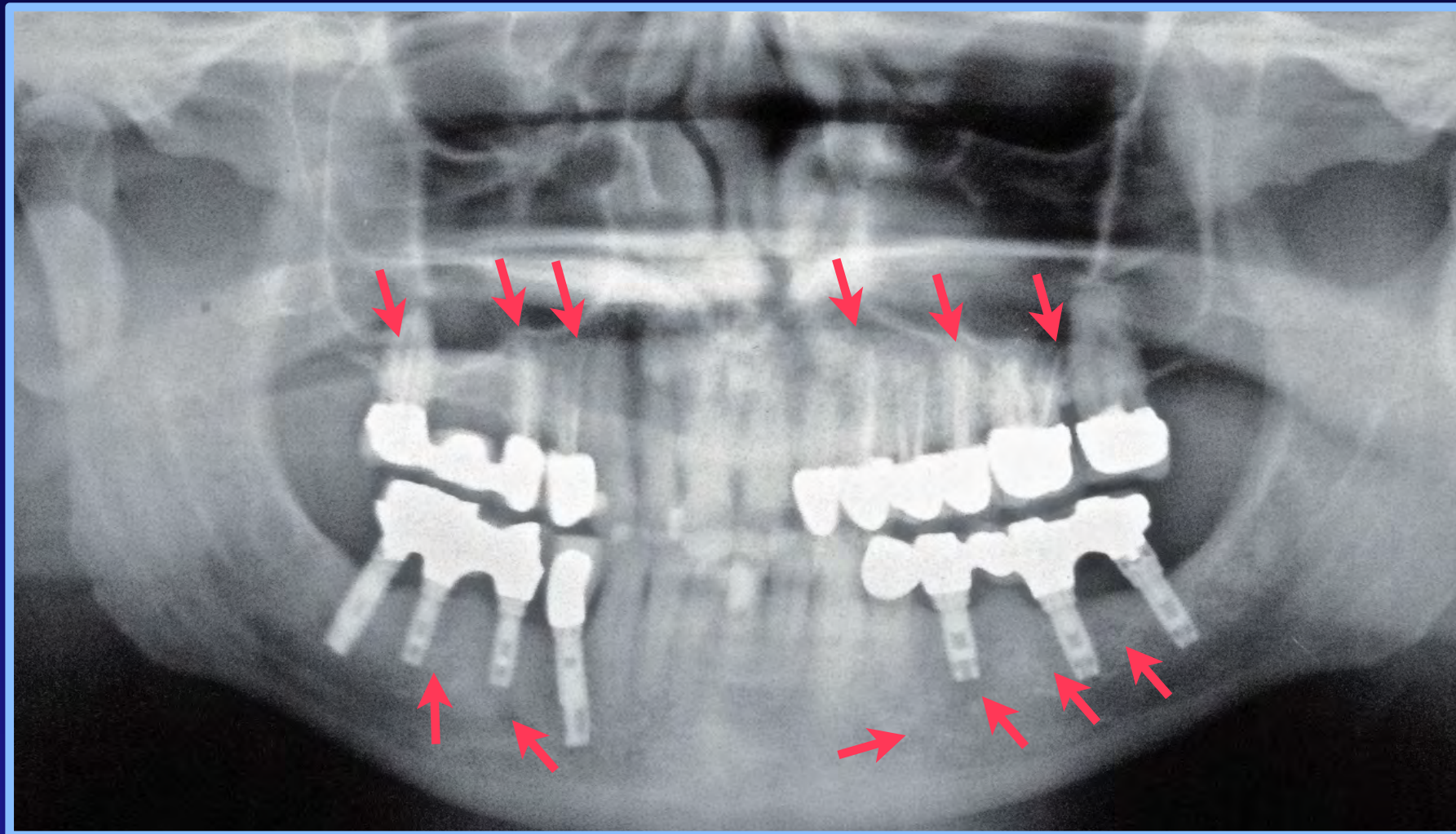


Disease can only occur in an unhealthy body.



Weeds can only grow in poor soil

Dental Cancer Connection



There are radiolucencies present in the areas of the implants and root canal teeth. The same pathogens that were diagnosed in the RC teeth and implants were also present in the tumor.

Dental Cancer Connection



Pat is alive, well and cancer free. Tx: maxillary left posterior bicuspids and molars were amputated, bone cleaned out and a non-metallic partial (acetyl resin framework and clasps). He underwent radical neck surgery. Daily Tx with Rife generator, raw green juices and raw food diet. He also had I.V. ozone (autohemotherapy) and vitamin program.

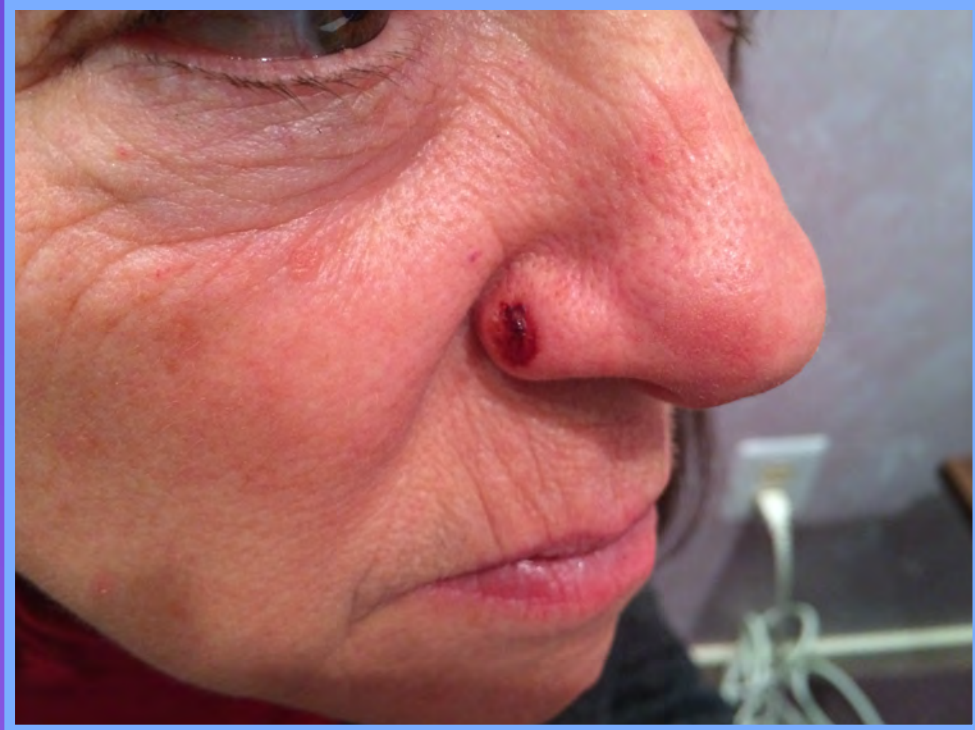
Analysis Paralysis

All the exotic medical testing
does not reveal the real source of the problem.

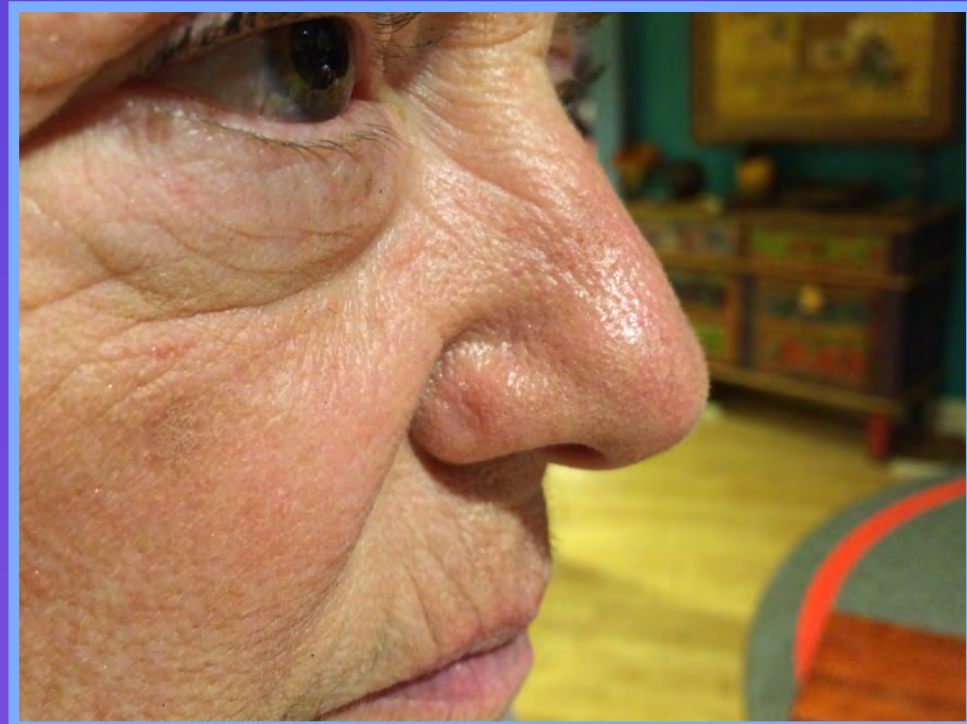Basal Cell Carcinoma Mercury Cancer Connection

CyberScan Professional System

Does scalar frequency technology really work?



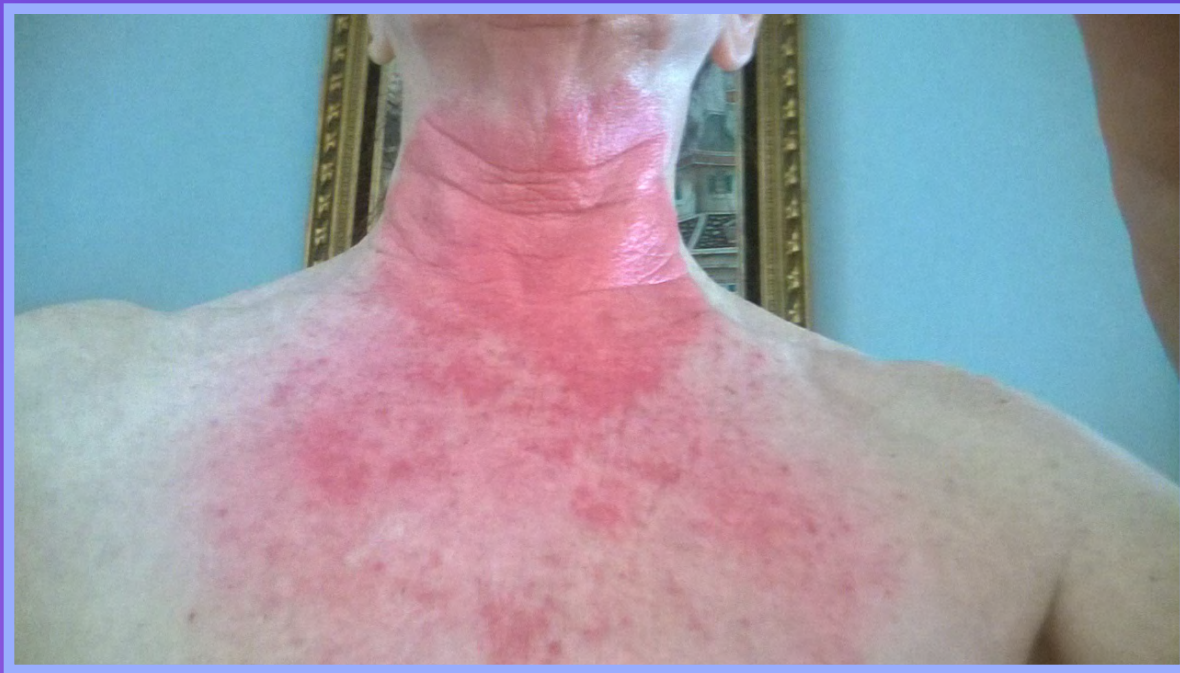*Basal Cell Carcinoma
Pre-Tx*



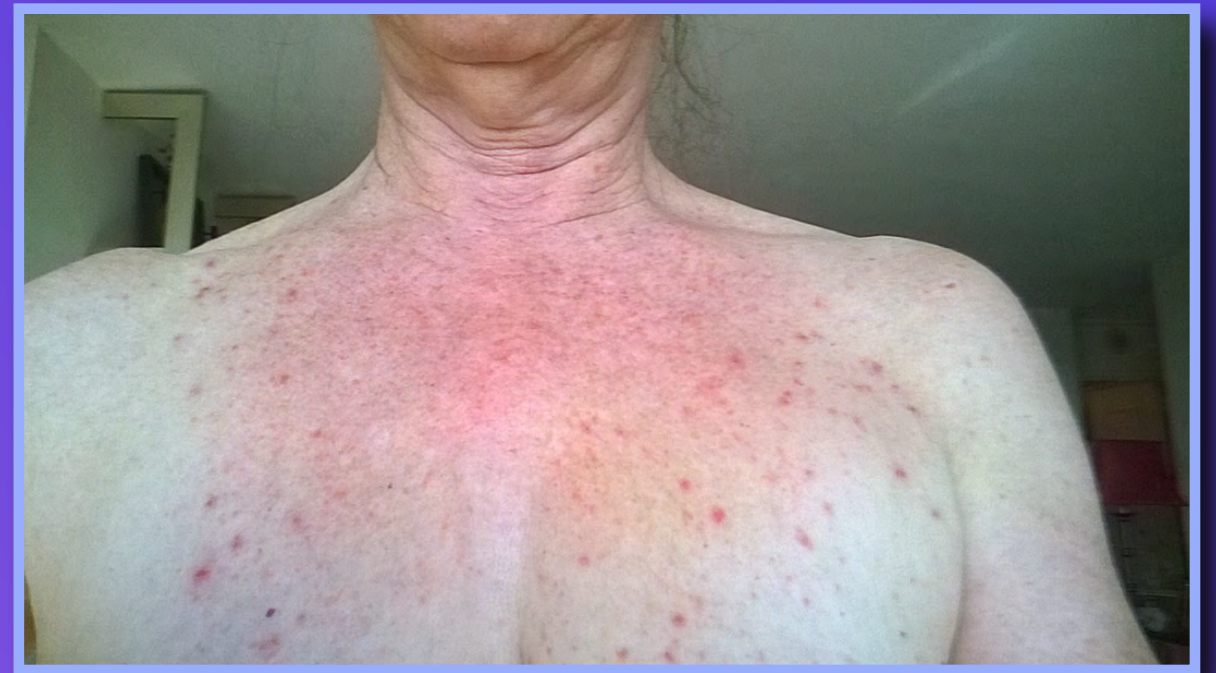*Basal Cell Carcinoma
1 year Post-Tx CyberScan
and nutritional therapy*

CyberScan Professional System

Detox reaction from CyberScan Tx and supplements



Mercury detoxing from thyroid



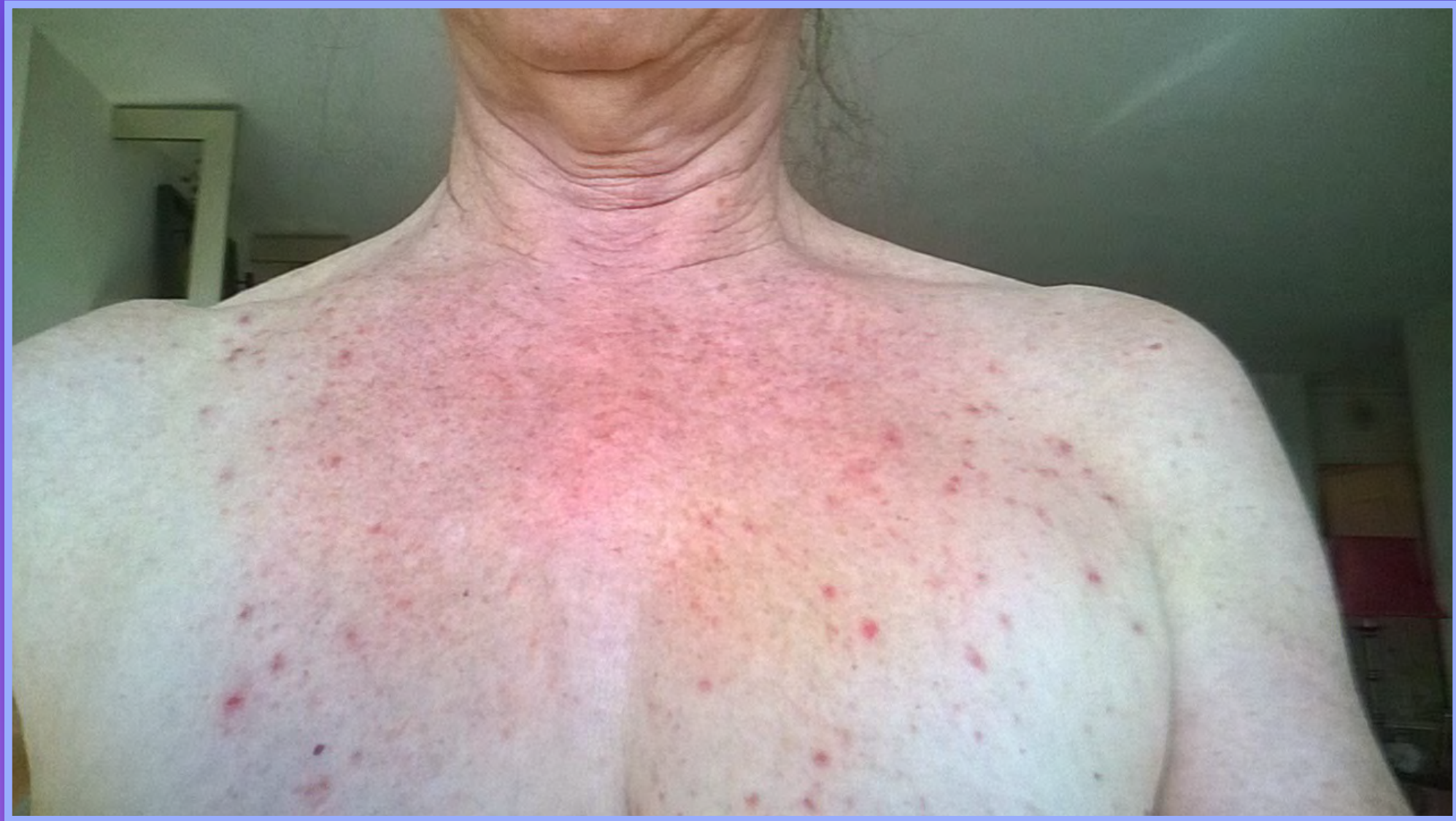Later stage of detox

Mercury was present in the basal cell lesion as well as many other toxins.

CyberScan Professional System

Detox Reaction From Supplements

Third stage of detox



Chief complaint was severe itching due to toxins exiting the body (candida, pesticides, heavy metals, vaccines, etc.)

PET Scan

Documents Stage

III Melanoma

Reversal

Stage III Melanoma

It is bad enough when a patient gets a diagnosis of cancer, but when you get a diagnosis of stage III melanoma it is a death sentence by conventional standards.

Eliot went the conventional route and took the two chemo drugs du jour, TAFINLAR + MEKINIST at a prescription cost of \$5,000 per month.

After experiencing a severe adverse reaction to these drugs and barely surviving his hospital stay, Eliot flew up from Florida to receive a more humane method of treatment.

Stage III Melanoma



Eliot was placed on specific food-based supplements to detox his liver and address the causative factors (heavy metals, pesticide, several viruses). Dietary guidelines were given and lifestyle changes recommended. In addition, he was advised to purchase a home ozone unit and treat himself for 20 minute a day.

Stage III Melanoma

Eliot was taking krill oil on a daily basis. Unfortunately, most people and physicians are not aware that **ALL fish oils are rancid at room temperature**. Ingesting rancid oils on a daily basis corrupts the cell membranes, lowers the oxygen intake, and decreases energy production in the mitochondria within the cells. The result is congestive heart failure, COPD, and cancer all of which Eliot had.

In six weeks, Eliot's congestive heart failure resolved. In two and a half months, Eliot's swollen and discolored thigh lesions dissipated and was over ninety-five percent gone. On April 18, 2019, Eliot had a PET Scan and it revealed a dramatic reduction in metastasis to the point of non-existence. In four months, his cancer was gone documented by PET scan.

Lung Cancer

Root Canal

Cancer Connection

CARCINOMA RIGHT LUNG



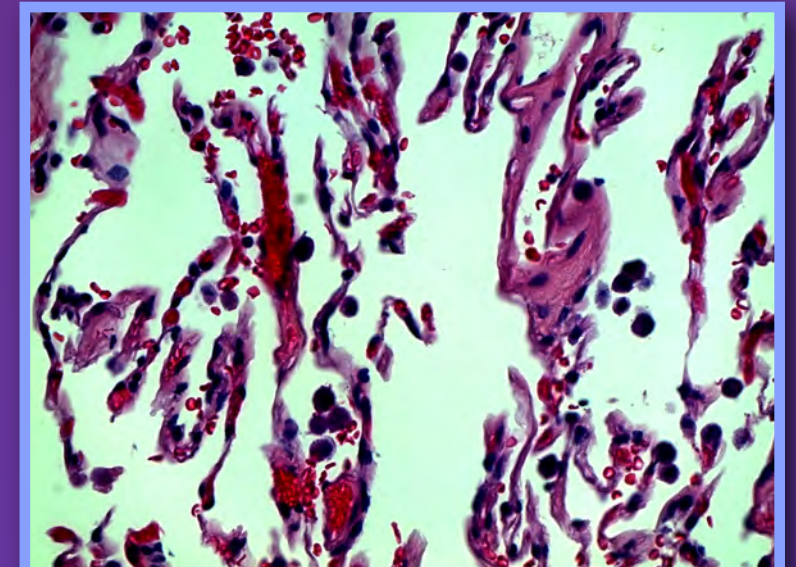
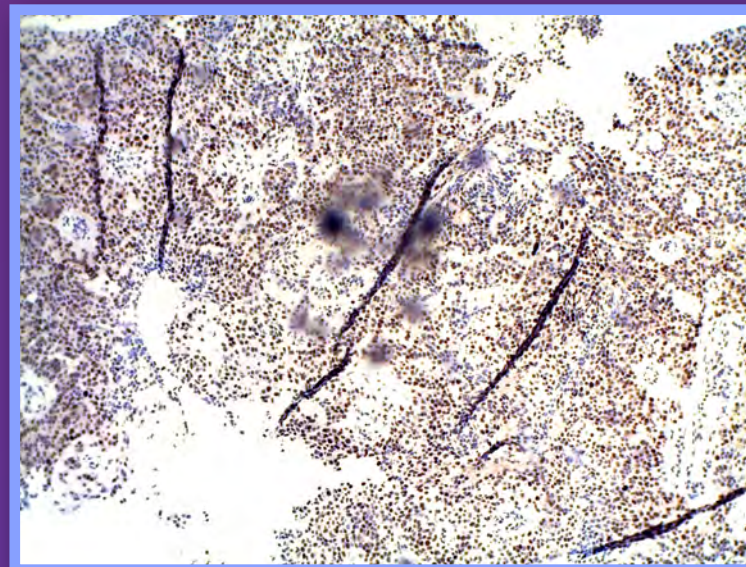
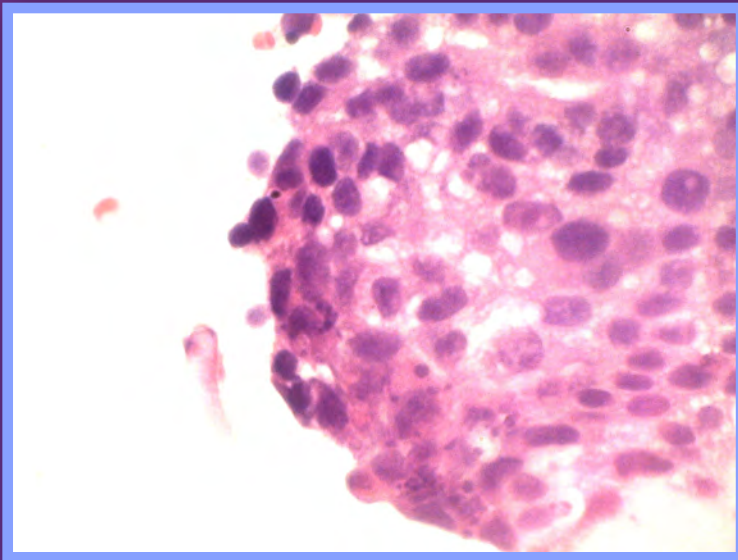
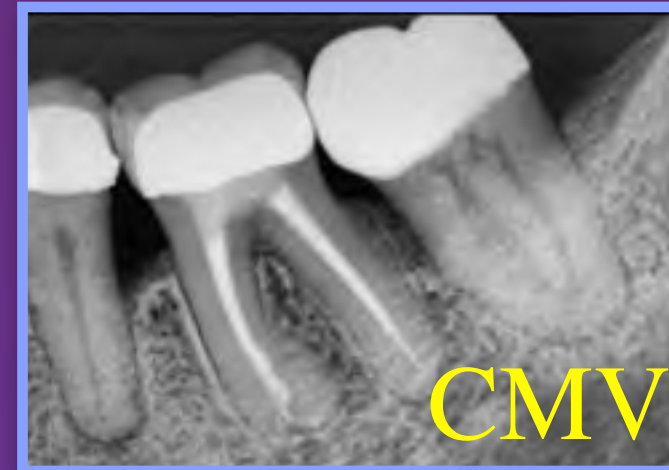
Carol K. developed right lung cancer.

Traditional Tx: cut tip of right lung off where cancer was present. The patient refused chemo or any other Tx.

Six months later the cancer appeared in the left lung. Patient refused any surgical intervention. Carol was referred to my office by her chiropractor.


LUNG CANCER

Pathology slides were tested energetically



Quantum Testing Dx: CMV, Hg, and a pesticide in the cancerous tissue!

LEFT LUNG CANCER

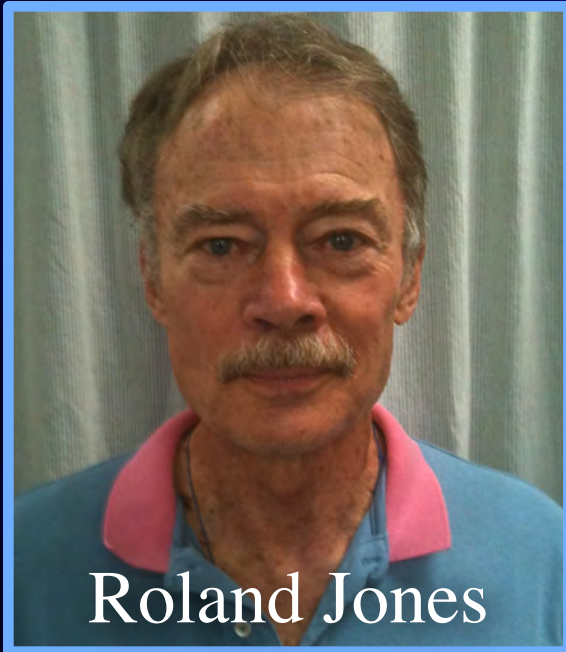


Carol K. was placed on a nutritional program to detox her liver, open up drainage, chelate the Hg, pesticide, and remove the CMV. Also the mandibular left molar was extracted. Extraction site **Tx:** O₃, Ionic Ag, Sanum remedies that were tested compatible for the patient. **Additional Tx:** Theraphi and CyberScan. The squamous cell carcinoma disappeared totally in six months.

Stage IV Throat Cancer

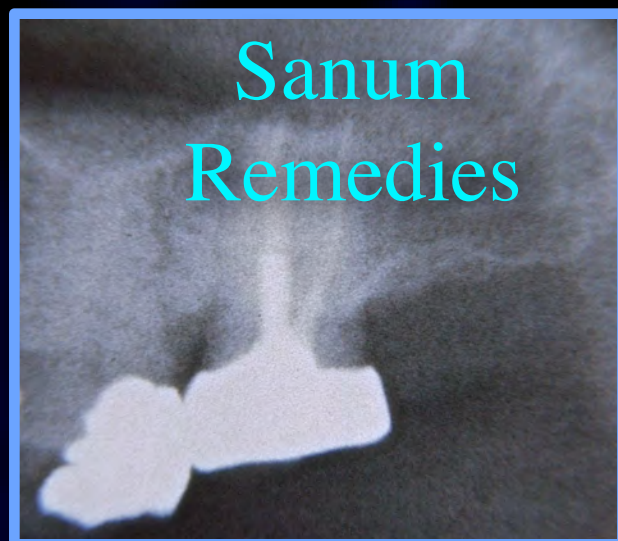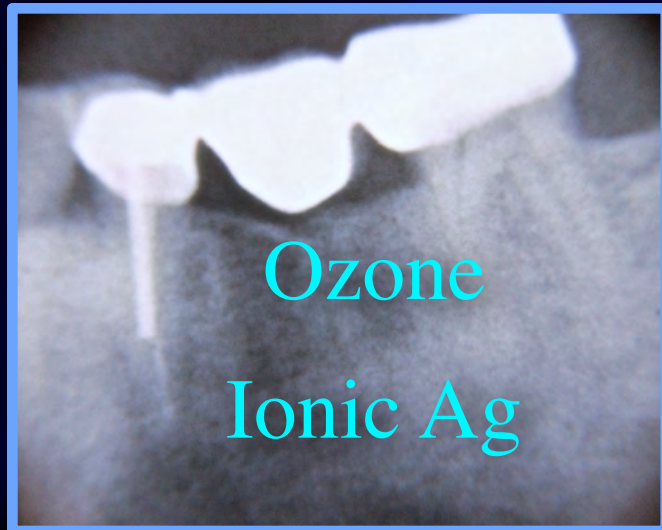
Root Canal Cancer Connection

Cancer Dental Connection



Roland had documented stage IV throat cancer with bilateral swollen cervical lymph nodes.

DX: Three infected teeth were present: lower left second bicuspid and second molar and maxillary left second molar. The same pathogens (Strep viridans and Tuberculinum) present in the three teeth were also present in the swollen cervical lymph nodes and throat cancer.



Tx: Extraction of the three infected teeth, Rife frequencies, raw juices, food based supplements and IPT totally **resolved the cancer in three weeks**. Roland has been cancer free for over 9 years.

PET Scan Report

07/15/09 13:47 ST. MARY MEDICAL CENTER (215) 710-2000

Page 1

St. Mary Medical Center
1201 Langhorne-Newtown Road Langhorne, PA19047
215-710-2185
Diagnostic Imaging

PATIENT NAME: JONES,ROLAND S
MED REC NO:M009211786
ACCT NO.:LP0307111088
ORDER NO:0715-0007

DOB:07/01/1940 AGE:69 SEX:M
PT CLASS:REG CLI
PT ROOM/BED:
DEPT: Pet

ORDERING DR.: CHACK, BENJAMIN S DO
CC:CHACK,BENJAMIN S DO; KIPP,JOSEPH MD;

ATTENDING DR.: CHACK,BENJAMIN S DO

REASON FOR EXAM: CA OROPHARYNX

COMMENTS:

ADMITTING REASON: OPOPHARYNX CA

PREGNANT: LMP:

ORDERED DATE/TIME: 07/15/09 1029
REPORT DATE/TIME:07/15/09 1346

PROCEDURE: PET/CT Skull to Thighs
REPORT NO.: 0715-0366

Status: Signed

Whole-body PET scan dated 07/15/09

History: Oropharyngeal cancer

Attenuation corrected imaging of the neck, chest, abdomen and pelvis was performed on a dedicated PET scanner following intravenous injection of 8.77 mCi of FDG. Blood glucose was 106 at the time of injection. Small field-of-view scan of the head and neck region is again performed, in addition to whole-body PET scan. Comparison is made to prior study of April 22, 2009.

Neck: Previously described asymmetry of the right tonsil remains stable in appearance. There is no evidence for new mass-effect or mass. Again noted is a minimal amount of nonspecific FDG uptake along the right pharyngeal and lingual tonsils, with maximum SUV in the range of 3.5. There is no evidence to suggest recurrent or residual focally increased FDG uptake or adenopathy within the neck.

Chest: Negative

Abdomen: Negative

Pelvis: Negative

Bone marrow: Negative

Impression:

1. Again noted is mild residual asymmetry and mild increased nonspecific FDG uptake associated with the right pharyngeal tonsillar region, unchanged from the prior study of April 2009. There is no evidence to suggest recurrent or increasing oropharyngeal mass. There is no evidence for developing cervical adenopathy or other metastatic disease.

TECHNOLOGIST: MCM
READING DOCTOR: COHEN,DANIEL J MD

SIGNED: COHEN,DANIEL J MD
PRINTED: 1347

PAGE:1 OF 1
PATIENT NAME: JONES,ROLAND S
MR#: M009211786
REPORT#:0715-0366

July 15, 2009

Oropharyngeal Cancer

Examination Report

September 3, 2009

September 3, 2009

Joseph Kipp M.D.
Village At Newtown Medical Center
2700 South Eagle Road, #100
Newtown, PA 18940

RE: Roland Jones
DOB: 07/01/1940

Dear Dr. Kipp,

Roland Jones was seen for followup today.

Enclosed are my findings:

Vitals: BP: 135/93 Pulse: 85

CC: Patient presents for throat pain.

HPI: no new complaints , status post carcinoma of neck

Exam:

ENMT:

Ears: External Ears: Inspection reveals normal ears. Canals within normal limits, but no cerumen in the auditory canals Tympanic membranes: intact and normal mobility.

Nose: External nose WNL. Internal Nose: Nasal cavity clear. Mild deviation of the nasal septum. Bogginess, hypertrophy and pallor of the turbinates bilaterally.

Oral Cavity: Lips appear normal and healthy. Dentition is in good repair. Gums appear healthy. Examination of the tongue appears normal. Submandibular and parotid ducts are patent bilaterally. Hard palate normal in appearance.

Oropharynx: Appears normal. Examination reveals base of tongue is soft, but does not reveal base of tongue mass. Soft palate normal in appearance. Uvula midline and normal in size. Tonsils , right tonsillar fossa within normal limits Posterior pharynx is normal.

Neck: Palpation reveals crepitation of the midline cartilages, but no tenderness. right neck mass, resolved Trachea midline. Thyroid is normal to palpation.

No Evidence of Disease

Assessment #1: 146.9 Cancer Of Oropharynx

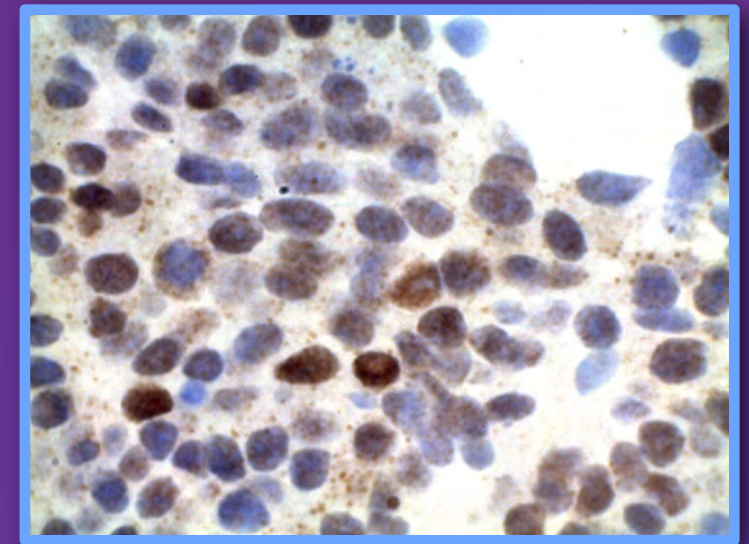
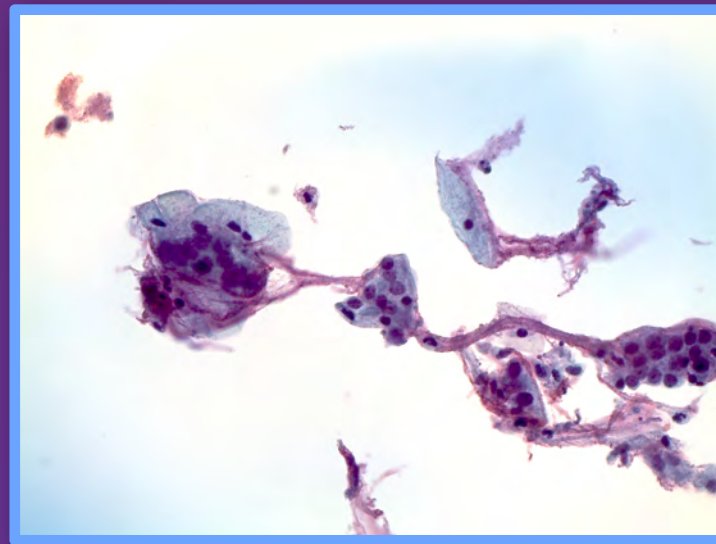
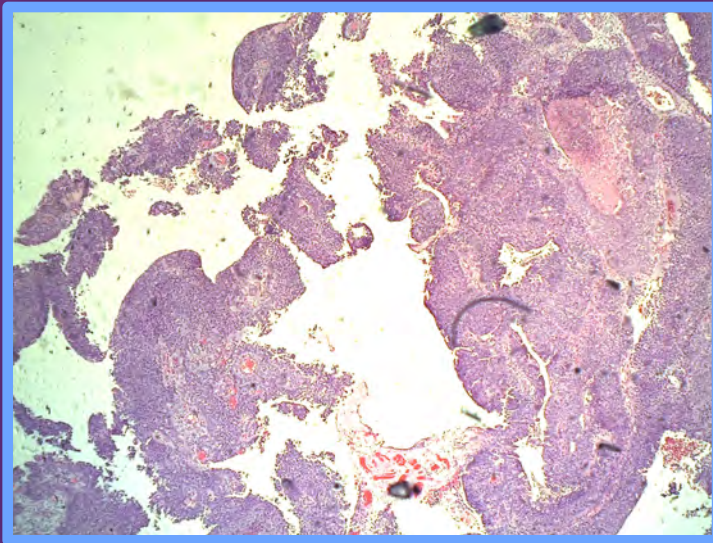
Plan:

Comments : No Evidence Disease, will observe and follow up in 2 months

**Grade III
Endometrial wall
Cancer**

**Necrotic Pulp
Cancer Connection**

GRADE III ENDOMETRIAL CANCER



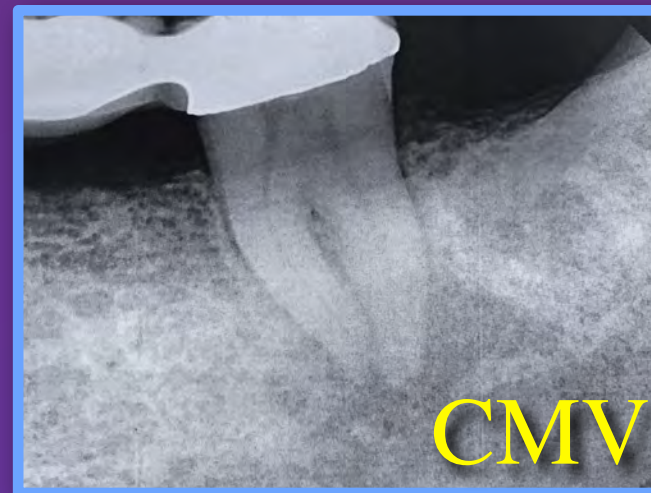
CMV and Hg were present in the cancerous tissue

MUST remove the “Splinters” or initiators!

GRADE III ENDOMETRIAL CANCER



- Infected lower left 1st molar



- Hypothyroidism
- Pseudomonas aeruginosa in thyroid

Acute Myeloid Leukemia Toxic Chemical Exposure

ACUTE MYELOID LEUKEMIA



- Hypothyroidism
 - CMV, Lyme, tetanus, carbryl
 - Hypoadrenia
 - Tooth #31 CMV
 - Tooth #18 CMV
- Low testosterone
 - Chemtrail exposure

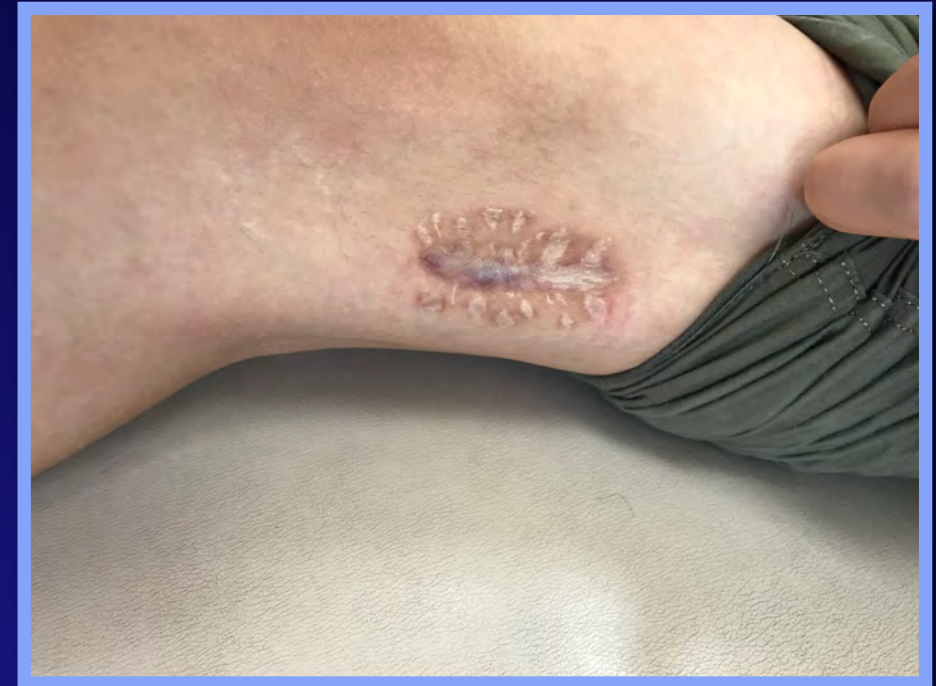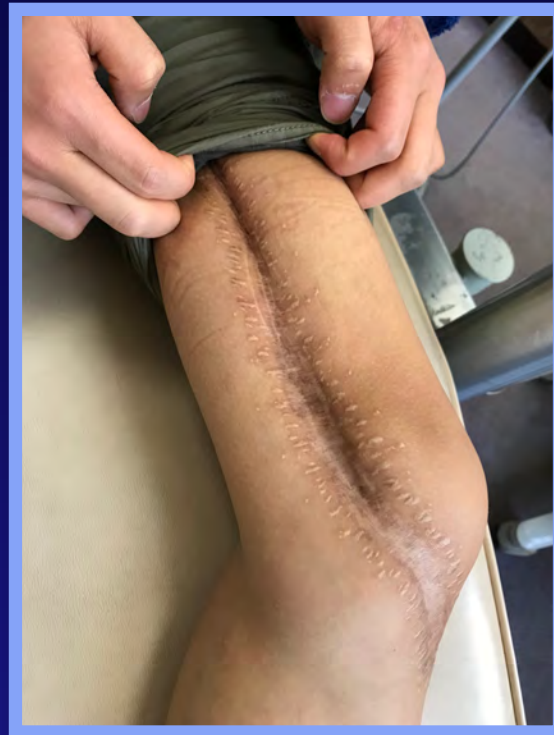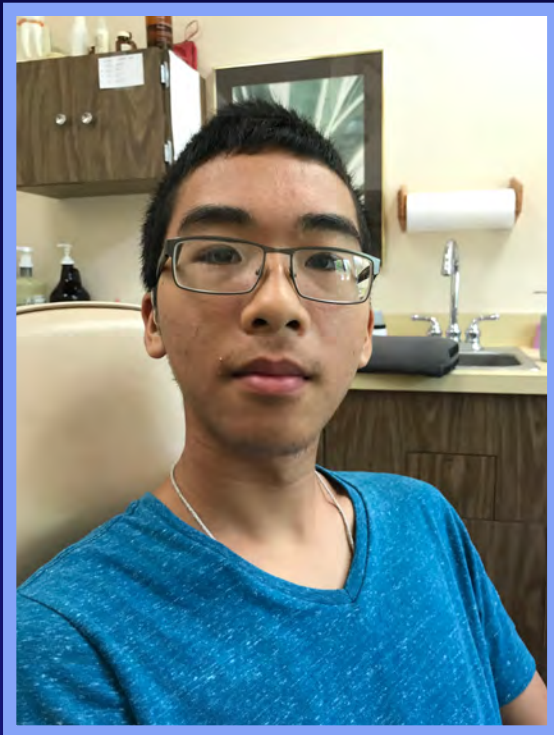ACUTE MYELOID LEUKEMIA



- Ed McDade was told in May of 2014 he had 3 months to live.
- 4.5 years later Ed is alive and getting stronger with on going Tx.
- Survival rate among chemo Txed patients over 65 yrs. 2.4 months.

Osteosarcoma of the Left Leg

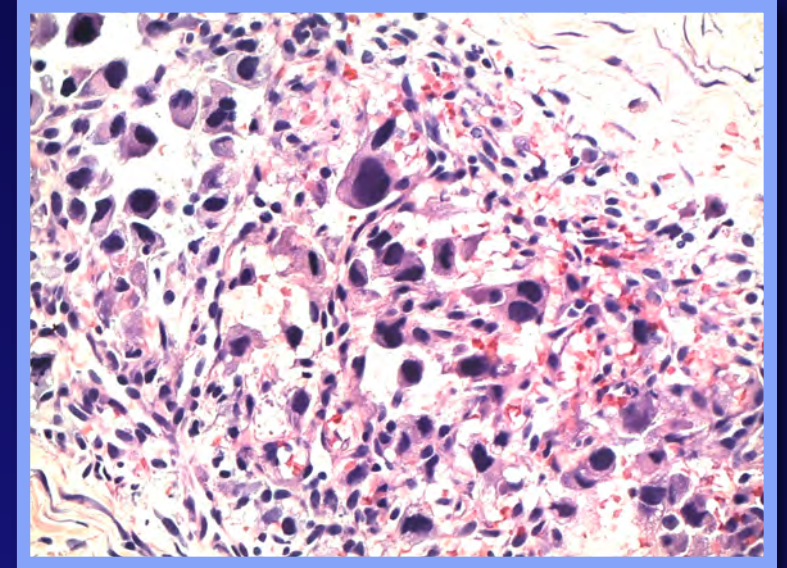
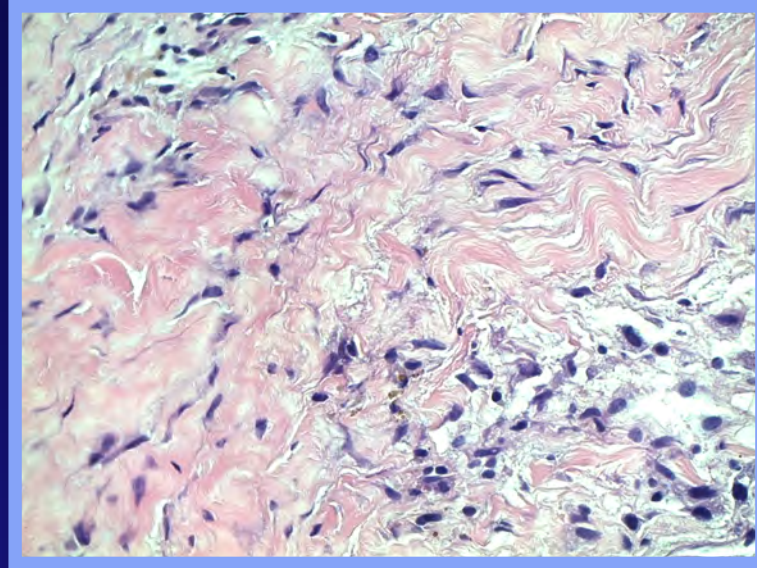
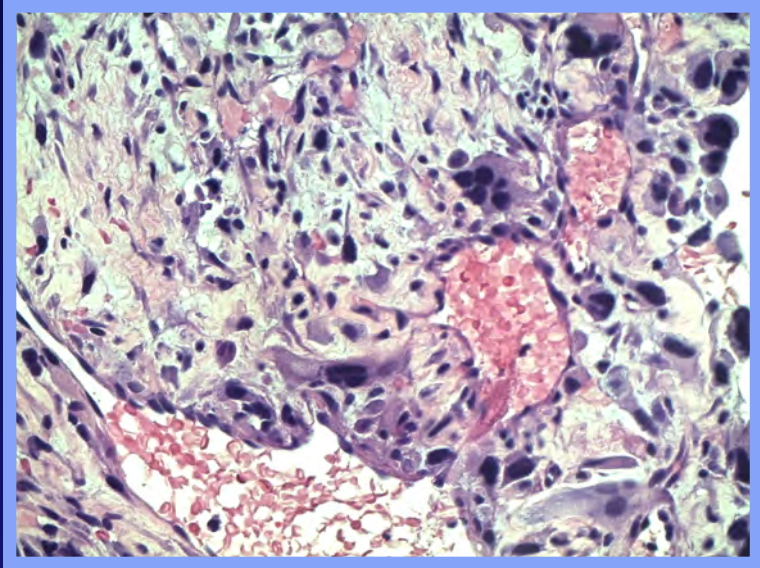
Ryoya



Ryoya is a 17 year-old male who developed osteosarcoma in his left leg. The patient was in constant pain when he was first examined.

Conventional Tx cut out the “cancer” and instituted chemo therapy. He developed a pseudomonas infection, which stopped the chemo Txs; four surgeries were performed to remove the infection and they had to replace the rod in his femur.

Ryoya



Quantum testing of the pathology slides revealed glyphosate, CMV, aluminum, mercury, and cadmium in the cancerous tissue.

Six weeks after nutritional therapy was started his constant pain resolved. He is being treated with the Theraphi System (scalar energy), laser and Rife frequencies. Following removal of the glyphosate, all his allergies resolved. He is in total remission.

Why is the medical profession afraid of a natural cure for cancer?

Because they do NOT want to loose the golden goose.

NEW BOOK RELEASE

Remove the “Splinters” and Watch the Body Heal

Defining the Real Cause of “Disease”
and How To Fix It Naturally



A Vibrational Medicine Approach to Healing the Body
Secrets of Life, Longevity, and Anti-Aging

Dr. Gerald H. Smith

In an era of medical deceit, telling
the truth is a revolutionary act!

Remove the “Splinters” and Watch:

Facial pain, TMJ, cancer, auto-
immune diseases, Alzheimer’s,
chronic pain, migraines, bipolar
disorder, CHF, seizures, vertigo
and many more “diseases”
DISAPPEAR !

e-book: available at www.ghsdoc.com



*“It ain't what you don't know that gets you into
trouble.*

It's what you know for sure that just ain't so!”

Mark Twain

THE END

